An imaging approach of the Small Bowel Mesentery

e-Poster: EE-105

Congress: ESGAR 2013

Type: Educational Exhibit

Topic: Diagnostic / Mesentery and Peritoneum

Authors: L. Andrade[1], A. Figueiredo[2], C. Antunes[1], L. Curvo-Semedo[1], J.F. Costa[1], H.V. Rodrigues[1], F. Caseiro-Alves[1]; [1]Coimbra/PT, [2]Viseu/PT

1. Learning Objectives

slide01.jpg

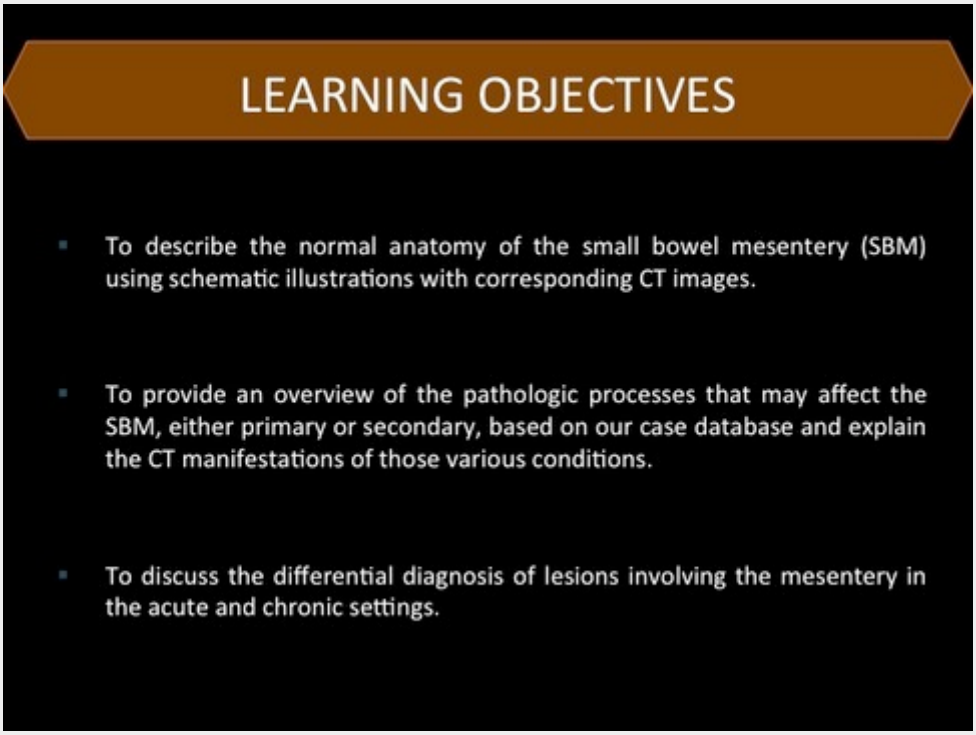

Learning objectives

slide02.jpg

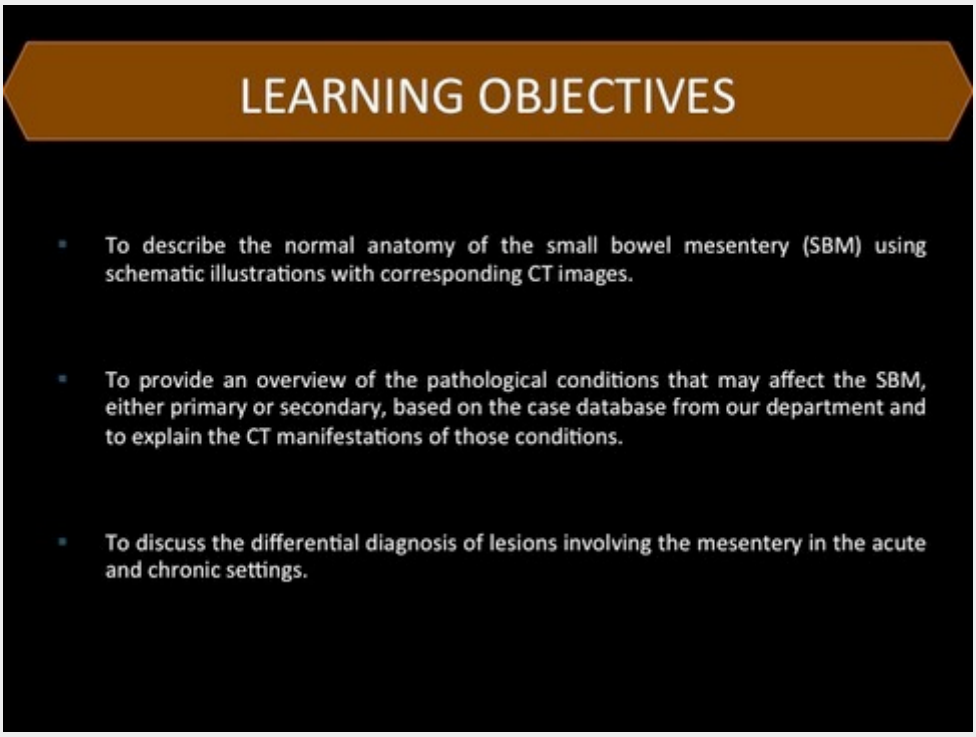

2. Background

Background

slide03.jpg

BACKGROUND

- The root of the small bowel mesentery is located deep in the abdomen, where peritoneal and retroperitoneal pathological conditions may overlap.
- It is closely related to other intraperitoneal spaces (supra and inframesocolic) and the retroperitoneum. As such it is a common route of spread of patological conditions, namely infections and neoplastic processes.

slide04.jpg

REVIEWING ANATOMY

PERITONEAL CAVITY

- Potential space in abdomen between visceral and parietal peritoneum, usually containing only a small amount of peritoneal fluid (for lubrication).
- Divided in greater sac and lesser sac (omental bursa) that communicates with greater sac via epiploic foramen (of Winslow).
- The peritoneum is a serous membrane that consists of two layers which are continuous with each other. One parietal, attached to the posterior abdominal wall and one visceral, lining the external surface of viscera.
- The parietal peritoneum has reflections or folds that fix intraperitoneal organs to the posterior abdominal wall, forming the anterior limits of the retroperitoneum. The mesenteric root corresponds to the attachment of one of these folds.

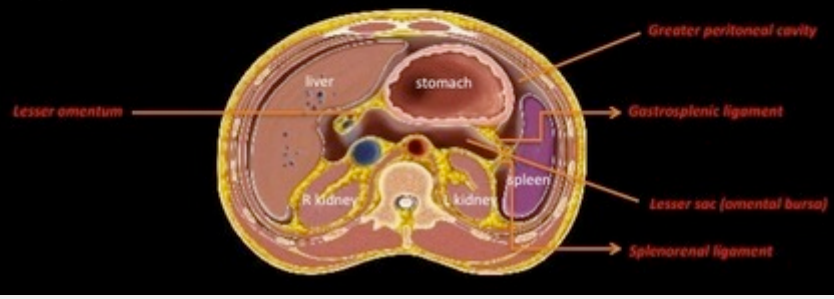

slide05.jpg

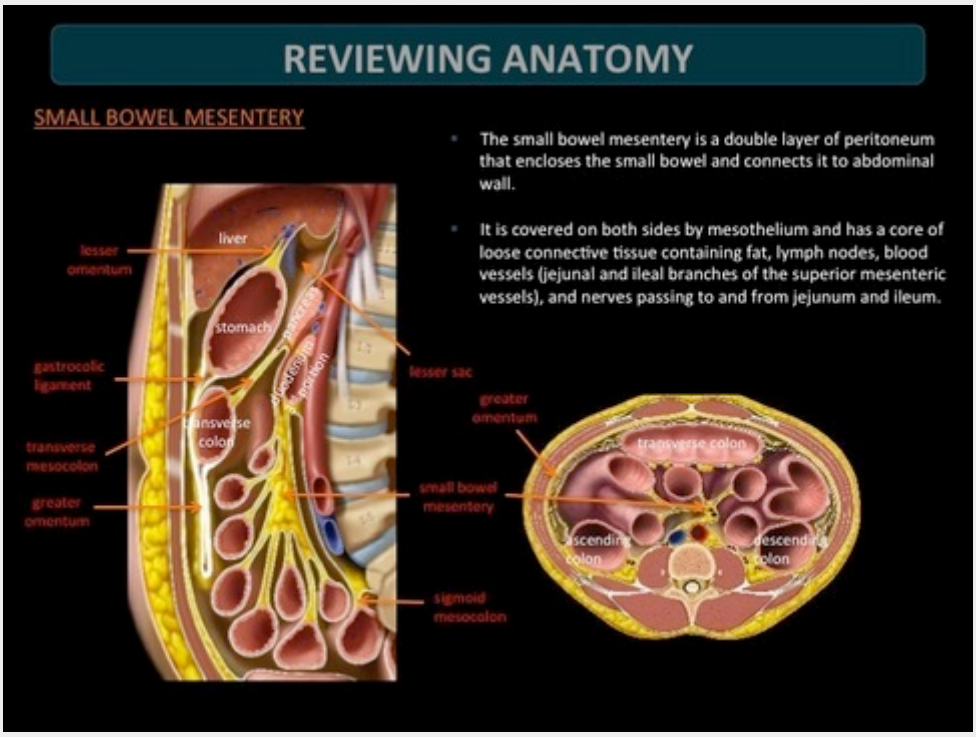

slide06.jpg

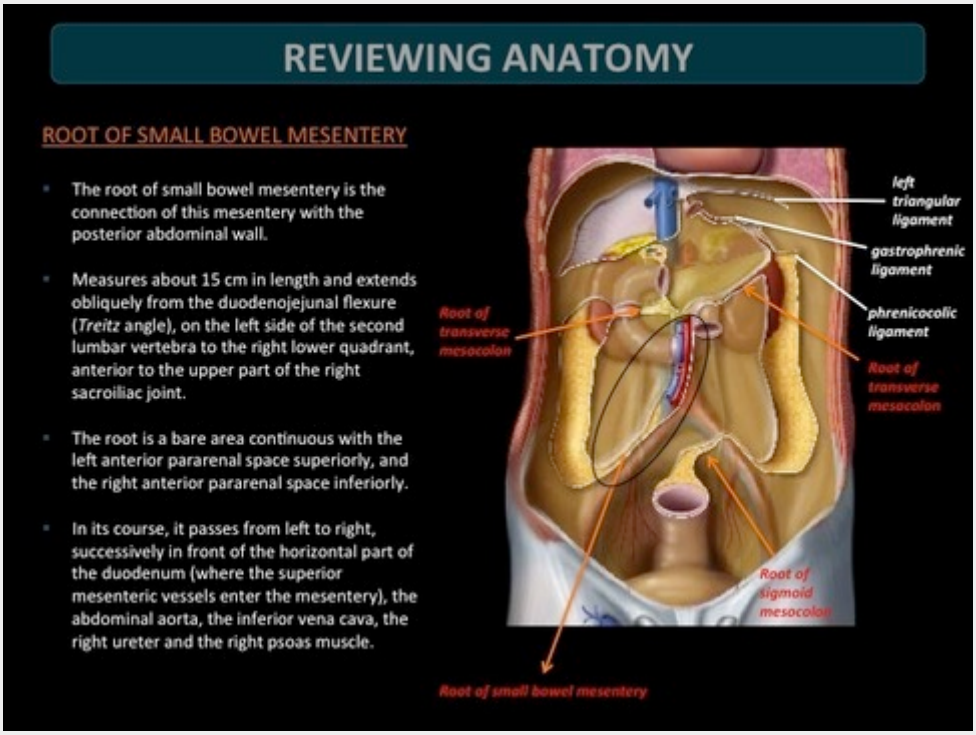

slide07.jpg

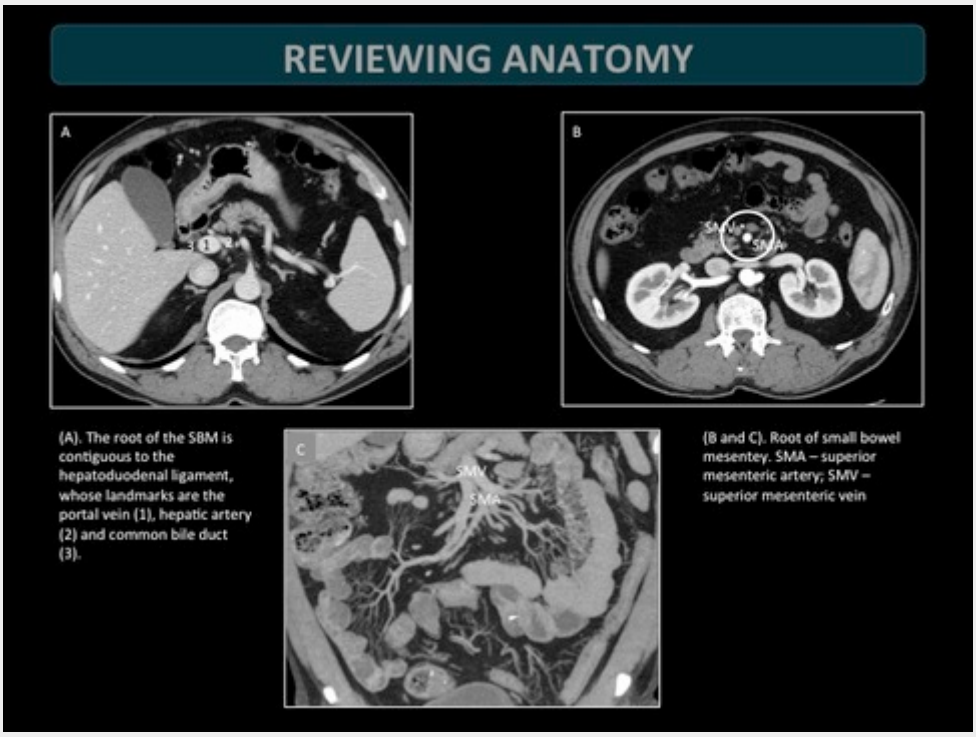

slide08.jpg

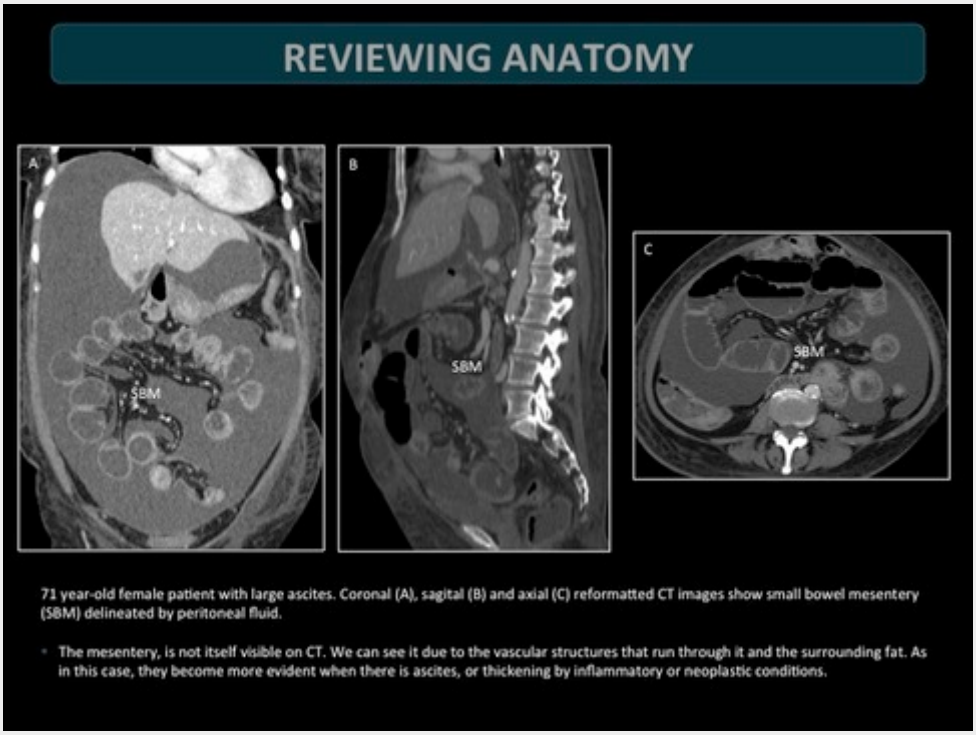

3. Imaging Findings/Procedure Details

slide09.jpg

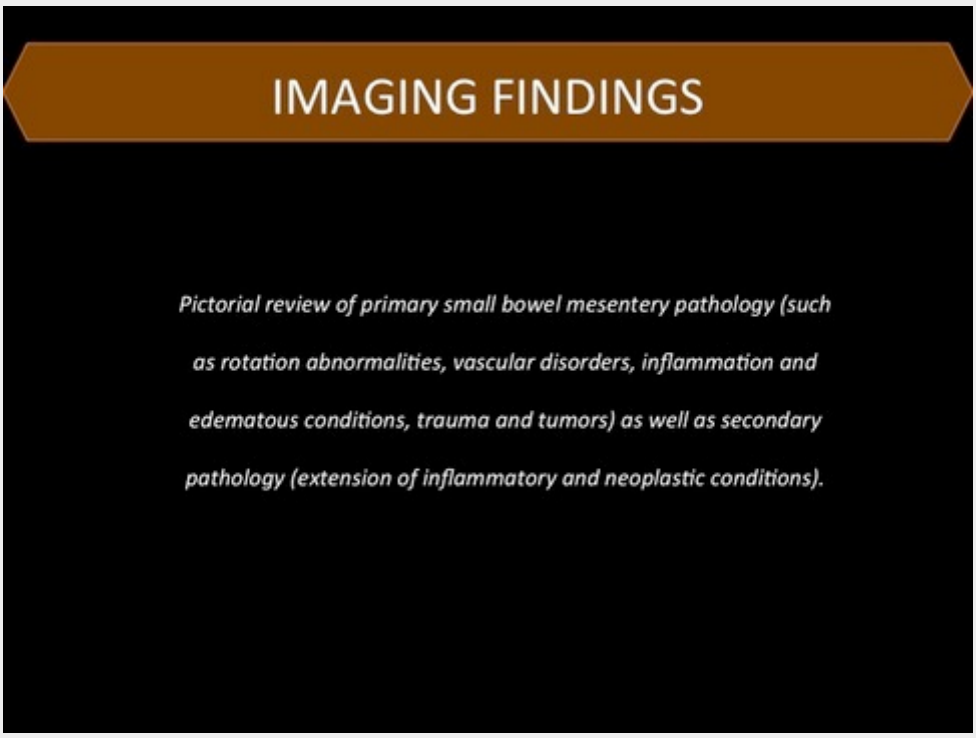

slide10.jpg

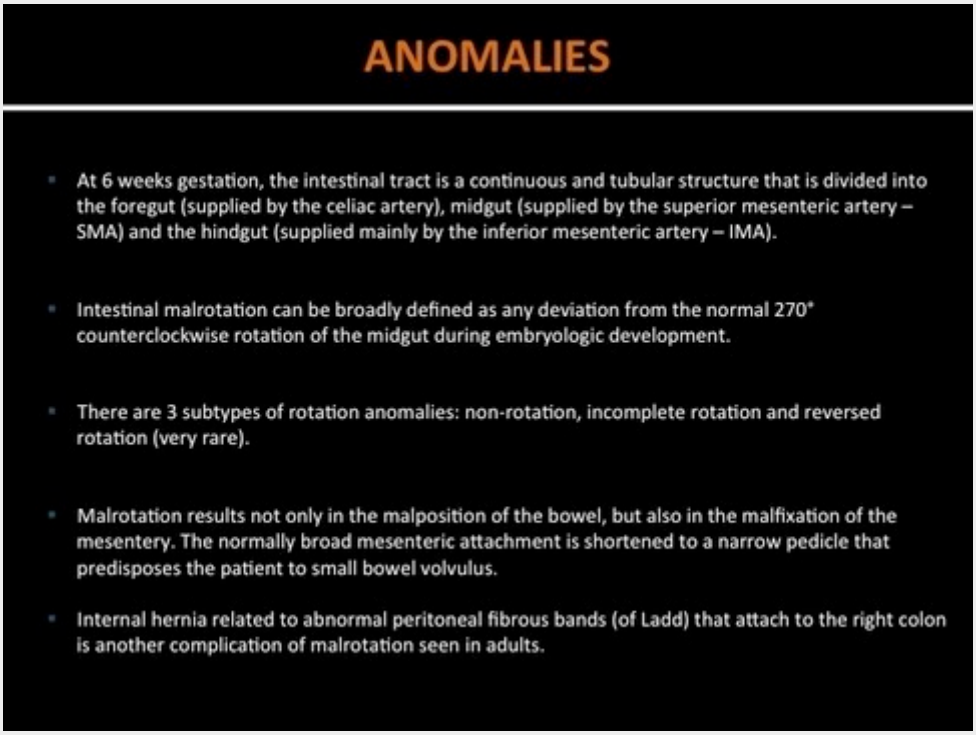

slide11.jpg

Rotation Anomalies of the Midgut

Nonrotation

- The midgut returns to the peritoneal cavity after rotating only 180º instead of the normal 270º.
- The small intestine is on the right side of the abdomen and the colon on the left side. The ileum crosses the midline from the right to the left to enter the cecum. The SMA is on the right side of the SMV.
- Most common anomaly and generally asymptomatic but increased risk for volvulus.

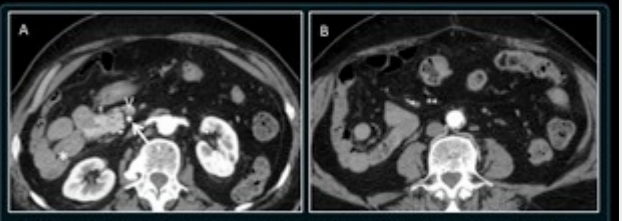

(A). 72-year-old woman with right abdominal pain. Axial contrast-enhanced CT scan shows inverted relationship between superior mesenteric artery (arrow) and superior mesenteric vein (v). Note the duodenojejunal flexure on the right (*).
(B). CT scan obtained through mid abdomen shows characteristic appearance of small bowel on right and colon on left.

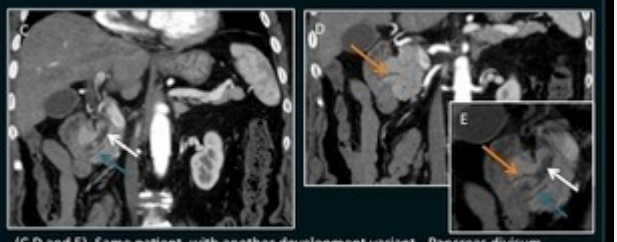

(C,D and E). Same patient, with another development variant - Pancreas divisum. Common bile duct (CBD) (white arrow); Dorsal duct (Santorini) (orange arrow); Small ventral duct (Wirsung) (blue arrow). CBD stone and associated obstructive cholangitis.

slide12.jpg

Rotation Anomalies of the Midgut

Incomplete Rotation

- Failure of the midgut loop to complete the final 90º of rotation.
- The cecum lies just inferior to the pylorus of the stomach and is fixed to the posterior abdominal wall by peritoneal bands passing over the duodenum.
- Increased risk of duodenal obstruction due to these bands or volvulus of the intestine.

Reversed Rotation

- Very rare
- The midgut rotates in a clockwise rather than a counterclockwise direction.
- The duodenum lies anterior and the transverse colon lies posterior to the SMA.
- Increased risk of obstruction of the transverse colon.

slide13.jpg

Internal Hernia

Paraduodenal Hernia

- Most common type of internal abdominal hernias; frequency - left side 3: 1 right side
- Result from congenital abnormalities in mesenteric peritoneal fixation.
- Frequently symptomatic; partial or complete obstruction of the small intestine (50%)

Left paraduodenal hernia (LPDH)

- Develops through a peritoneal defect (the paraduodenal or Landzert fossa) situated at the duodenojejunal junction (confluent zone of the descending mesocolon, transverse mesocolon, and SBM) and extends behind the descending mesocolon and the left portion of the transverse mesocolon.
- IMV it is the most important landmark of the duodenojejunal junction.

slide14.jpg

Left Paraduodenal Hernia

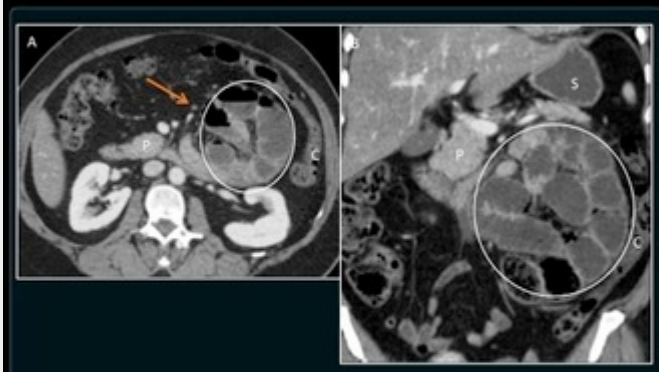

LPDH in a 50-year-old man with acute, intermittent epigastric pain. Contrast-enhanced CT scan of the upper abdomen shows a sac-like mass of dilated jejunal loops (circle) between the pancreatic head (P) and stomach (S in B). The descending mesocolon (C) and stomach are displaced laterally.
The inferior mesenteric vein is a landmark for the inferior mesocolon, which is located at the anteromedial border of the encapsulated jejunal loops.

- CT can demonstrate an encapsulated bowel loop that displaces the inferior mesenteric vein anteriorly, suggesting that the trapped loop is located behind the descending mesocolon.
- The trapped small-bowel loops are dilated; if they are strangulated, there is congestion of the SBM.

slide15.jpg

Right Paraduodenal Hernia

Right paraduodenal hernia (RPDH)

- Involves the mesentericoparietal fossa of Waldeyer, located just behind the root of the SBM.
- The SMA and SMV run along the free edge of the right paraduodenal hernia sac.
- Most frequent in nonrotation of the small intestine.

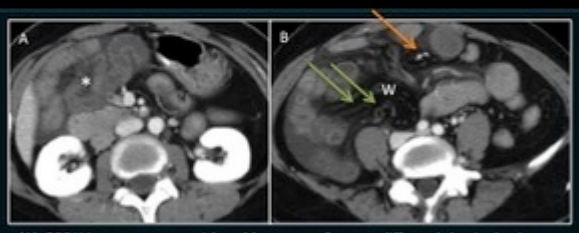

(A). RPDH in a young man with sudden onset of severe diffuse abdominal pain. Contrast-enhanced CT scan shows a sac-like mass of fluid-filled small bowel loops (*), most of which were jejunal and proximal ileal loops.
(B). The encapsulated bowel loops herniated through the fossa of Waldeyer (w), which is located behind the superior mesenteric artery (orange arrow) just below the transverse portion of the duodenum. The SMA is displaced anteriorly by the entrapped bowel loops and there is dilated and converging vessels (green arrows) in the mesentery.

- The superior mesenteric artery and right colic vein are located at the anterior-medial border of the encapsulated small bowel loops and are a landmark for right PDH.

slide16.jpg

Transmesenteric Hernia

- Transmesenteric (across small bowel mesentery) and transmesocolic hernias account for 8% of all internal hernias.
- Mechanical small bowel obstruction (SBO) is a common complication of these hernias.

- The bowel mesenteric defect itself is not visualized.
- Clustering of small bowel loops in association with proximal small bowel dilatation, with a transition zone to a normal or collapsed intestine.
- Abnormalities of the mesenteric vessels: the mesenteric vascular pedicle is characteristically engorged, stretched, and crowded; converging mesenteric vessels are located at the entrance of the hernial sac and there is displacement of the main mesenteric trunk.

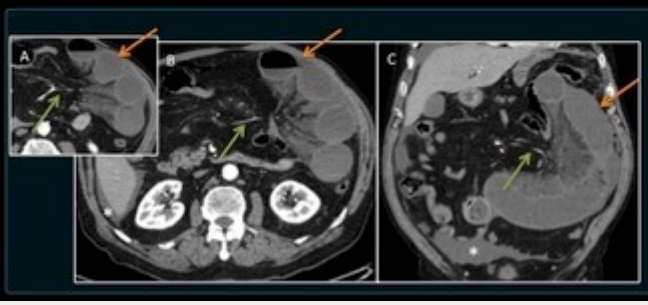

74 year-old man with SBO due to internal transmesenteric hernia.

Contrast-enhanced CT scan shows multiple dilated and fluid-filled loops of small bowel with air-fluid levels (orange arrows). There are stretched and converging vessels at the hernial orifice (green arrows) and ascitic fluid in the right iliac fossa and perihepatic (*).

As shown, this internal hernia causing SBO lead to focal segmental ischemia of the herniated small bowel loops.

slide17.jpg

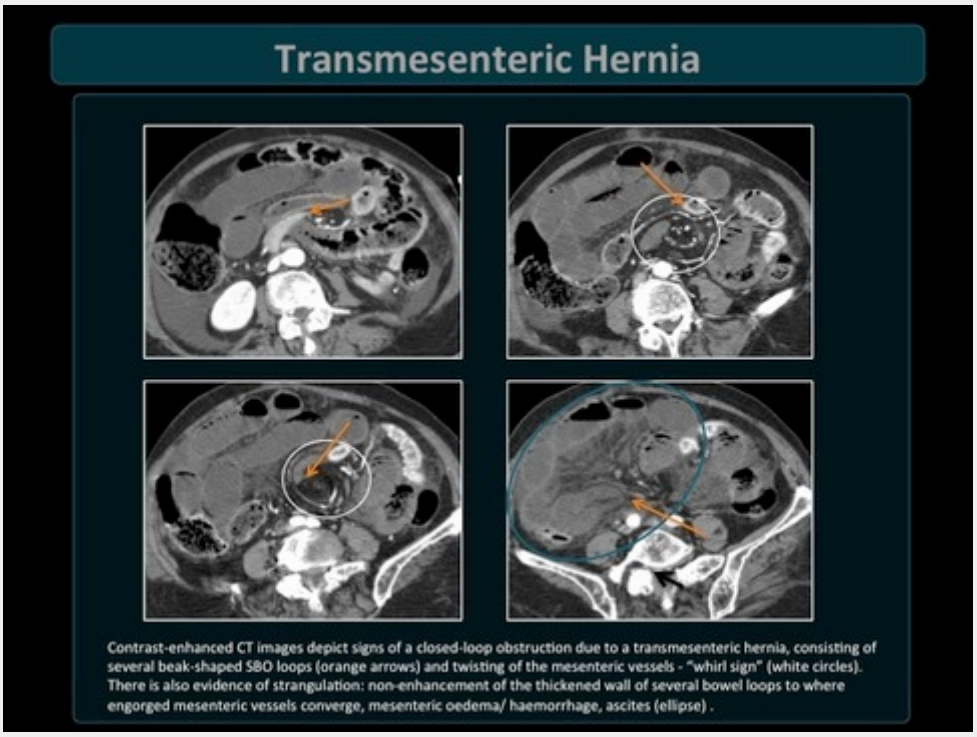

slide18.jpg

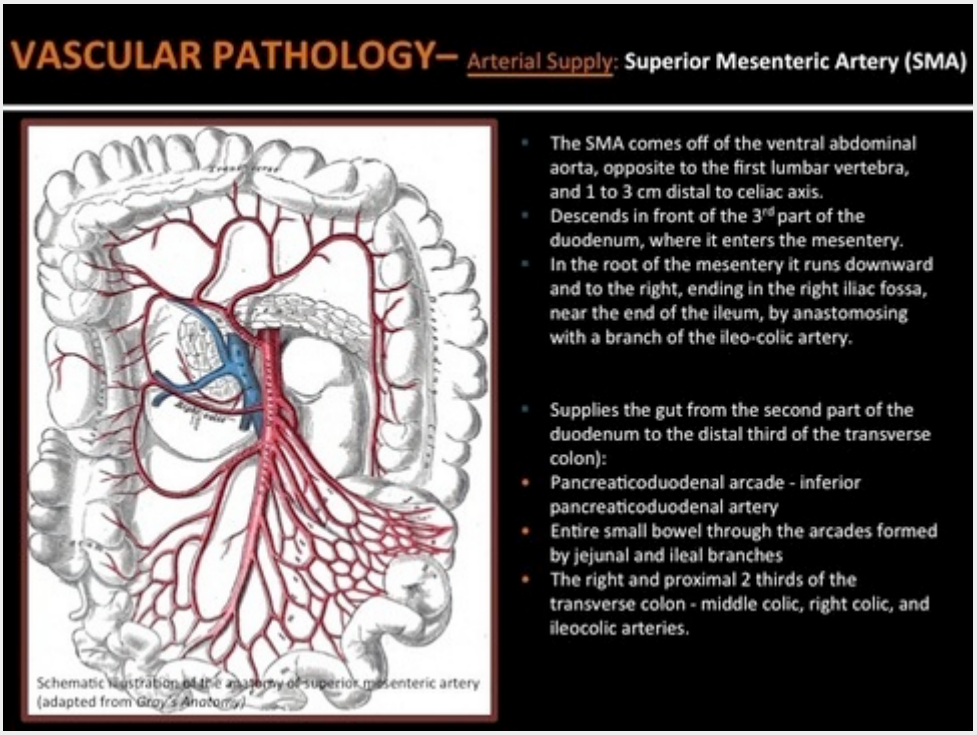

slide19.jpg

VASCULAR PATHOLOGY – Venous Drainage

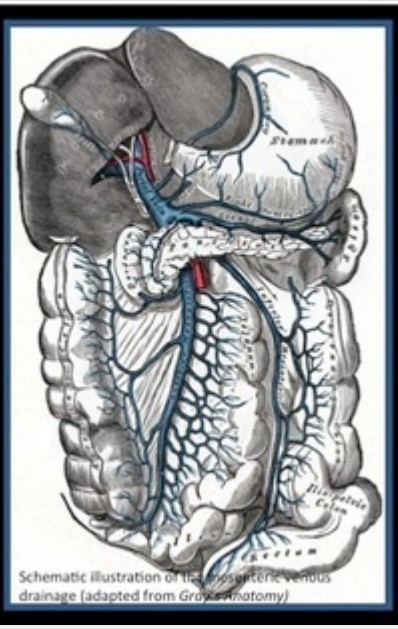

Schematic illustration of the mesenteric venous drainage (adapted from *Gray's Anatomy*)

- The mesenteric venous blood is drained by the portal vein, which is formed by the confluence of splenic vein and superior mesenteric vein (SMV).
- The mesenteric veins run parallel to the corresponding arteries.
- The inferior mesenteric vein receives supply from the left colic, sigmoid and superior rectal veins. It joins the splenic vein before its confluence with the SMV.
- The SMV receives the duodenal, pancreatic, right gastroepiploic, jejunal, ileal, right colic, and middle colic veins. The coronary veins (right and left gastric) drain directly into the portal vein.

slide20.jpg

Vascular Pathology – MESENTERIC ISCHEMIA

- Bowel injury during mesenteric ischemia is mediated by the injury of the tissue resulting from interruption of blood flow and by reperfusion which causes increased vascular and epithelial permeability with leakage of fluid into the bowel lumen, bacterial translocation and decreased intestinal blood flow.
- Ischemic Bowel Disease (IBD) can be acute or chronic and can range from reversible to transmural infarction with necrosis, intestinal bleeding and perforation, abscess formation and peritonitis.

MDCT – Evaluation of suspected Mesenteric Ischemia: BOWEL WALL
MESENTERIC VESSELS

slide21.jpg

ACUTE MESENTERIC ISCHEMIA

- **Arterial Occlusion**

- *Embolism* (50%): arrhythmias; valvular disease; myocardial infarction; cardiac aneurysm; aortic atherosclerotic disease; iatrogenic

- *Thrombosis* (10%): atherosclerotic disease; vasculitis; fibromuscular displasia; trauma; dissection

- **Venous Thrombosis** (10%): hypercoagulable states; sepsis; malignancy; portal hypertension; compression; pregnancy; surgery and trauma

- **Non-Occlusive Mesenteric Ischemia** (25%): heart failure; cardiac bypass; sepsis; systemic hypotension; burns; pancreatitis

- **Focal Segmental Ischemia** (extravascular) (5%): bowel obstruction; malignancy; surgery; radiation; vessel injury

slide22.jpg

ACUTE MESENTERIC ISCHEMIA – SMA Occlusion

- Hypodense *filling defect* of the arterial lumen

- *Decreased bowel wall attenuation* (submucosal edema and inflammation) or, less commonly, increased due to submucosal hemorrhage
- *Lack of bowel enhancement* or increased, delayed and persistent enhancement due to hyperemia (= good prognosis)

- *Very thin small bowel wall* (arterial occlusions) vs. circumferential bowel wall thickening (most common in venous occlusions)

- Transmural infarction: Intramural gas – *Pneumatosis Intestinalis; mesenteric and portal venous gas; pneumoperitoneum* (perforation of an infarcted bowel segment)

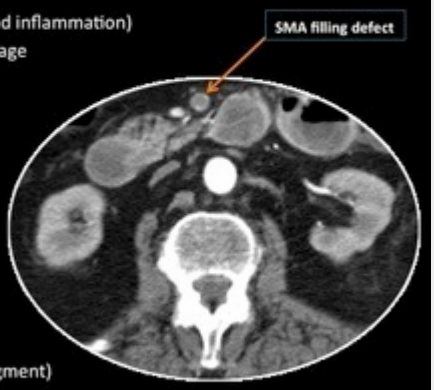

- *Mesenteric fat stranding* and *ascites* (more pronounced in venous occlusion)
- *Bowel dilatation* with fluid filled bowel loops

slide23.jpg

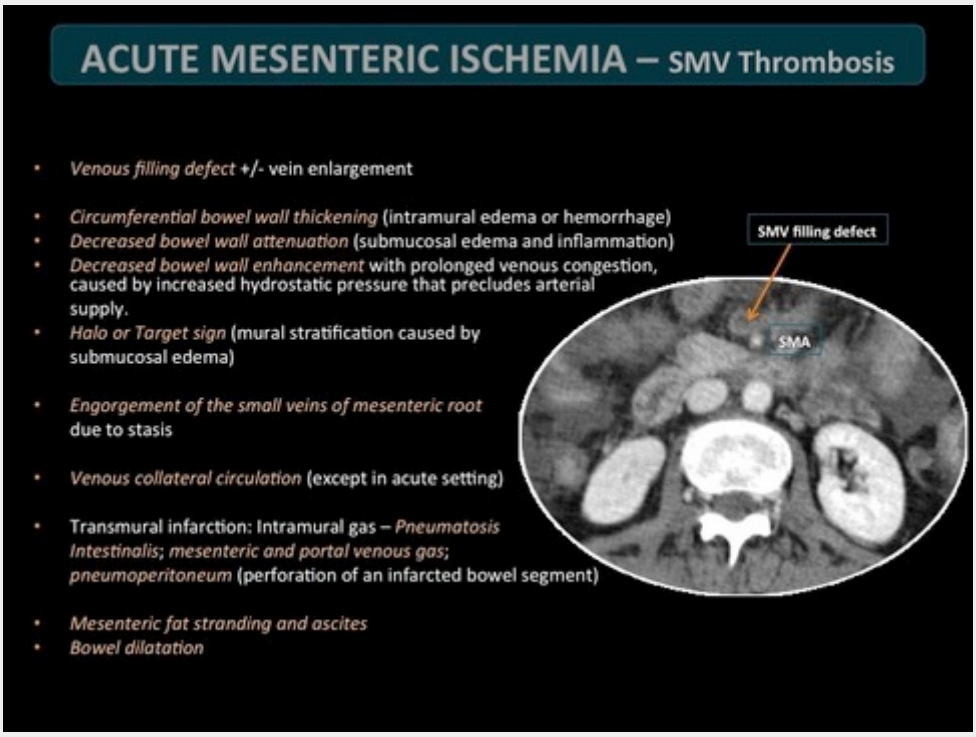

slide24.jpg

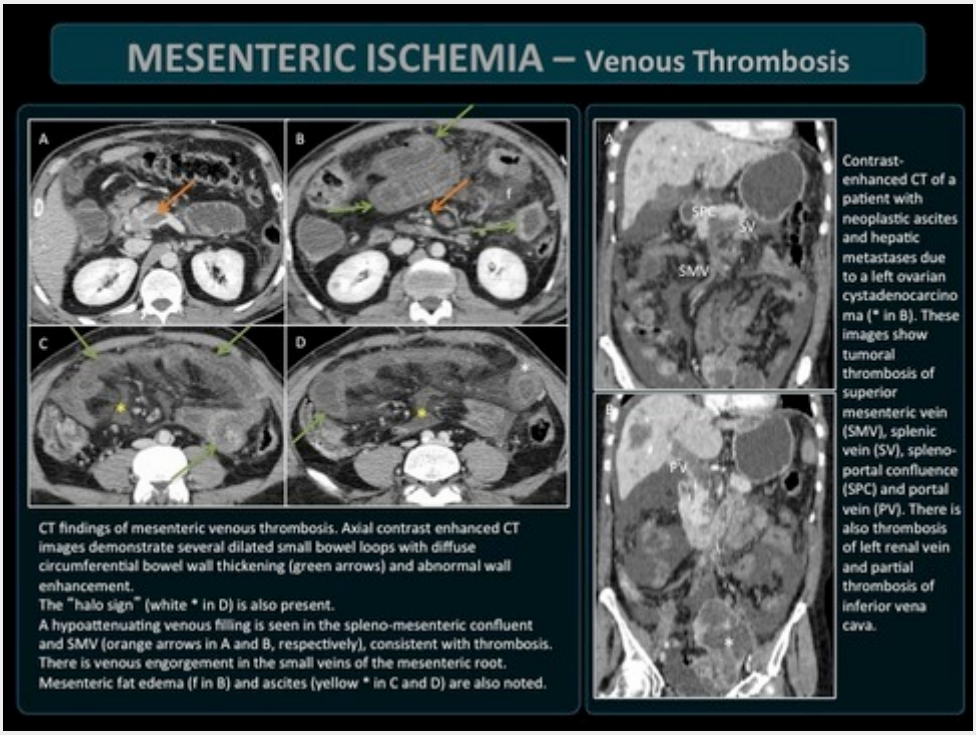

slide25.jpg

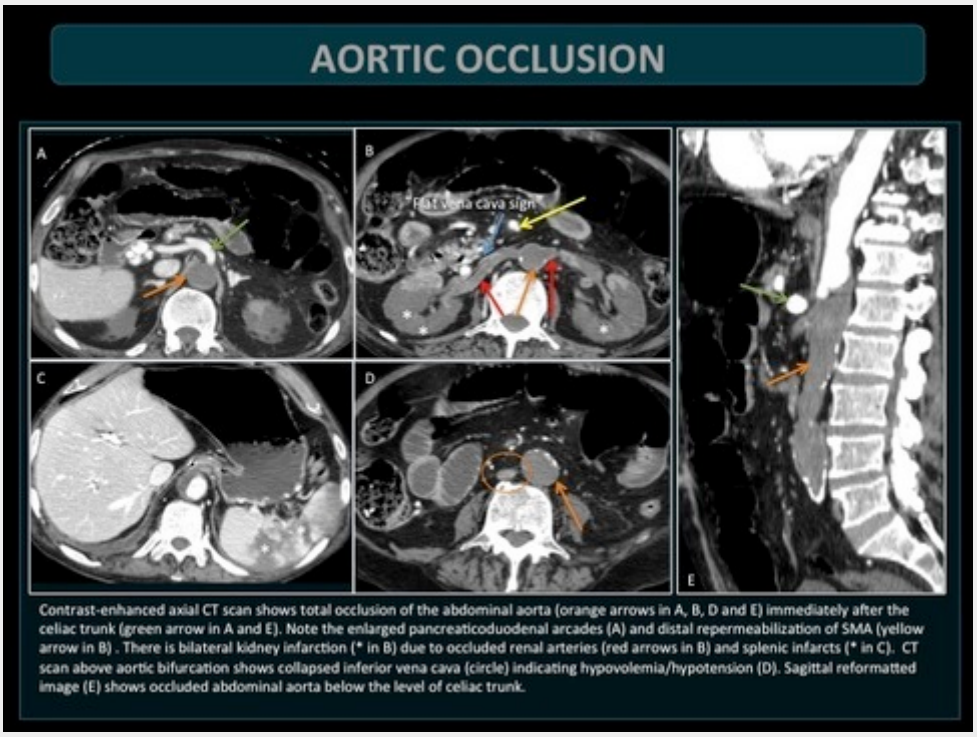

slide26.jpg

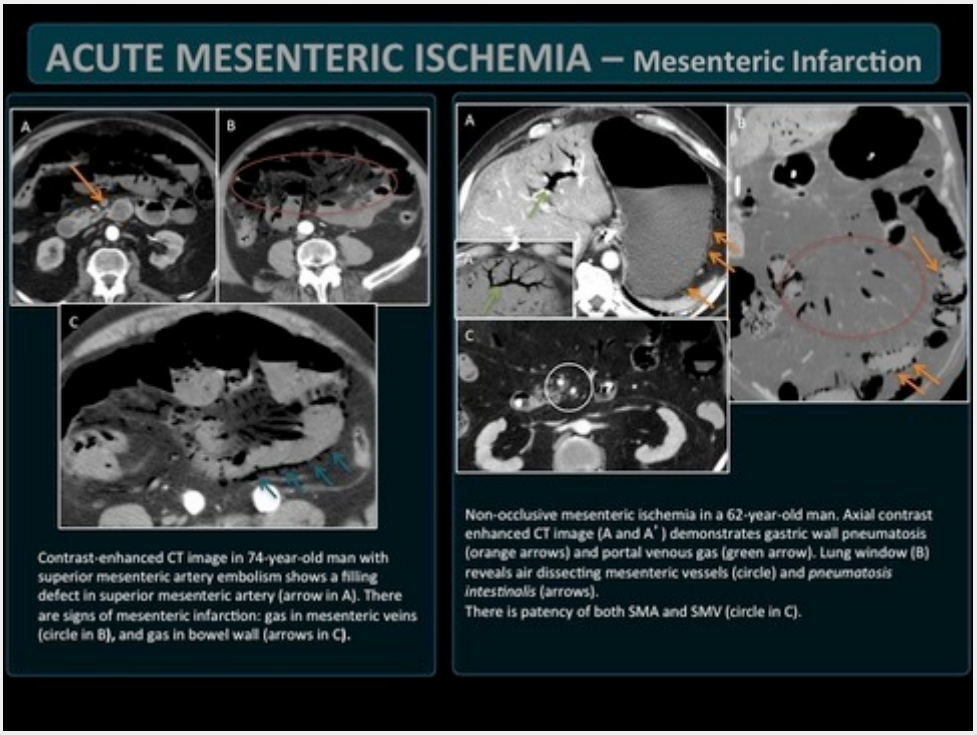

slide27.jpg

TRAUMA

- 5% of patients who suffered a blunt abdominal trauma have a mesenteric injury.
- The most common lesions are mesenteric lacerations with or without hematomas.
- The mesenteric side of the intestine is more prone to vascular tears, whereas the antimesenteric side is more prone to perforations.
- Mesenteric injury should be suspected (in the appropriated clinical setting) in a patient with reticulated increased attenuation of the mesenteric fat or a hematoma in the root of the SBM on CT.
- Other CT findings are mesenteric extravasation and hemoperitoneum, irregularity in mesenteric vessels or abrupt stop of mesenteric vessels.

slide28.jpg

Mesenteric Traumatic Injury

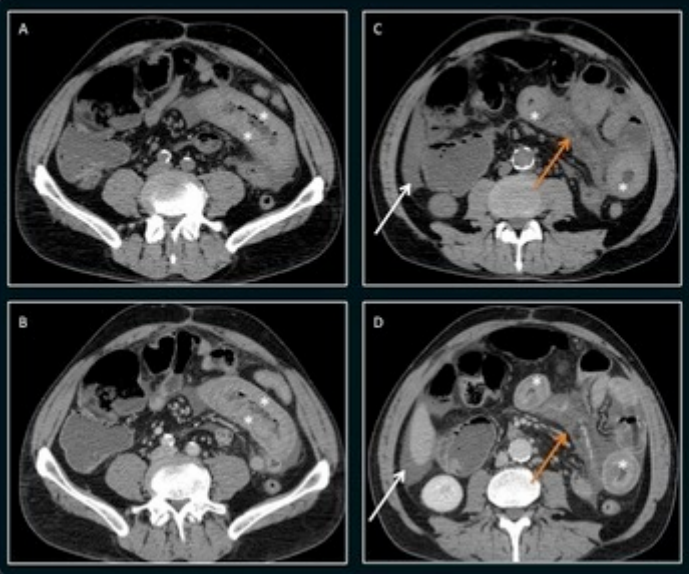

Axial non-enhanced CT images (A and C) demonstrate the presence of extensive and circunferential spontaneously hyperdense jejunal wall thickening (*). This finding is compatible with a focal intramural jejunal hematoma. There is also a mesenteric hematoma (orange arrow) and hemoperitoneum (white arrow).
After administration of contrast material (B and D) the hematoma is hypodense.

slide29.jpg

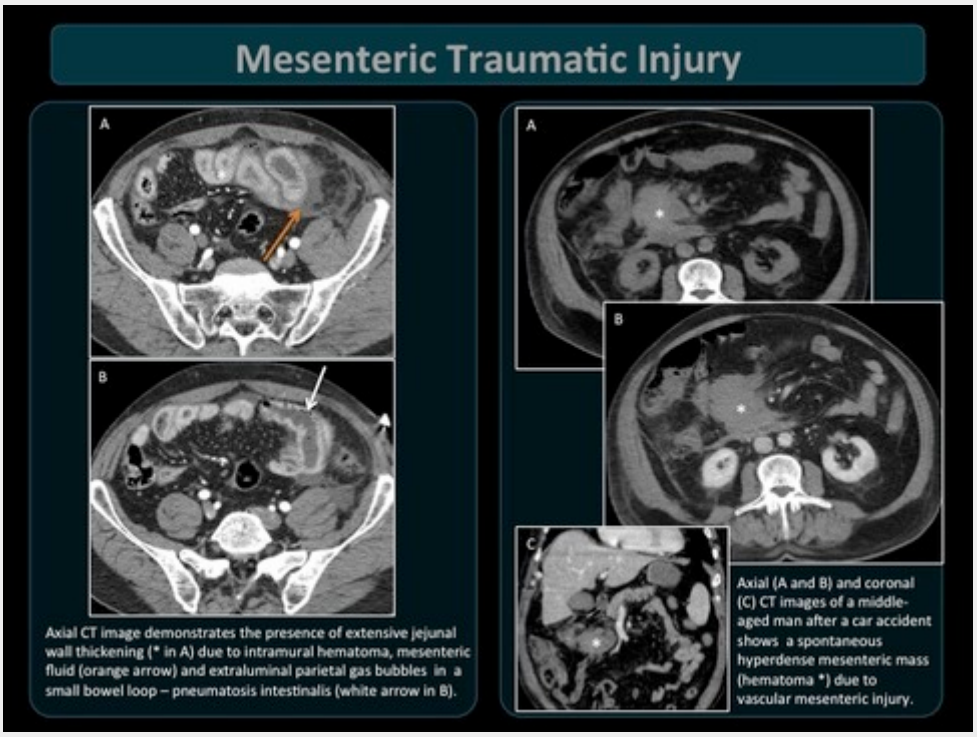

slide30.jpg

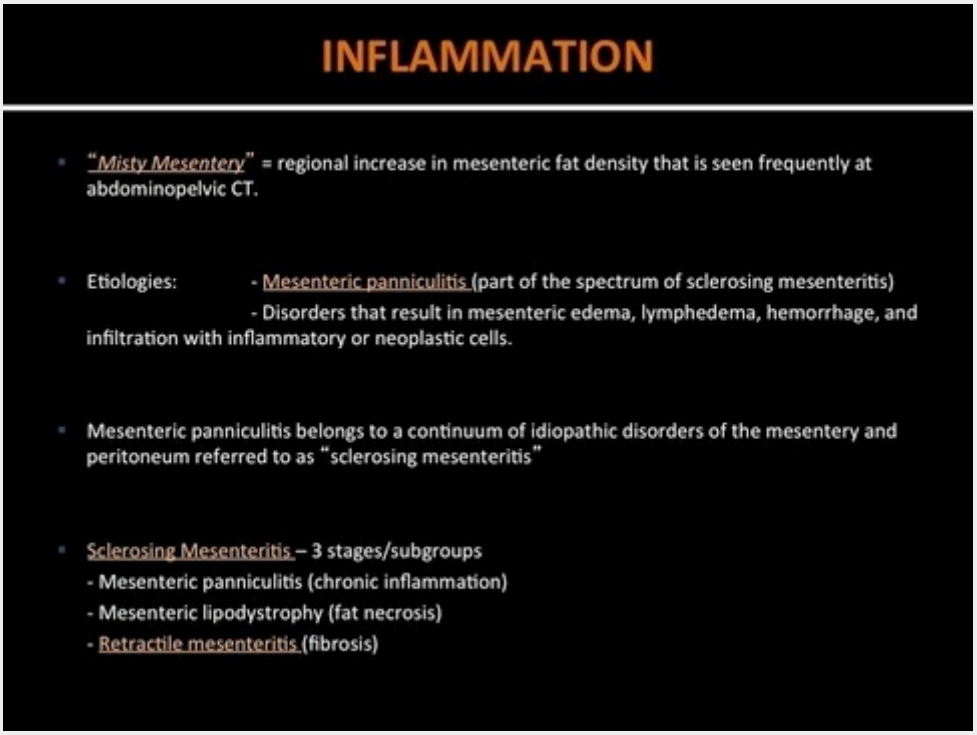

slide31.jpg

Mesenteric Panniculitis

- Chronic nonspecific inflammation involving the adipose tissue of the bowel mesentery (+ jejunal mesentery).
- May occur independently or in association with other disorders (vascullitis, granulomatous and rheumatic diseases, malignancies and pancreatitis).
- CT shows a mass-like area of heterogeneously increased fat attenuation that may displace local bowel loops but typically does not displace the surrounding mesenteric vascular structures.
- Some cases demonstrate a hyperattenuating stripe (pseudocapsule) surrounding the mass.
- Mesenteric lymph nodes are often seen within the region of segmental mesenteric stranding and may be enlarged.
- The "fat halo or ring" sign, refers to the preservation of normal fat density in the fatty tissue surrounding the mesenteric vessels and nodes.

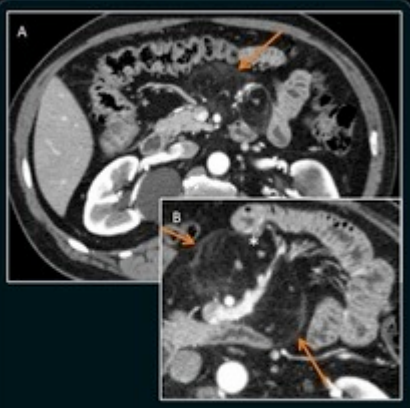

(A and B). Chronic abdominal pain in an elderly woman. Contrast-enhanced CT shows infiltration of the jejunal mesentery, set off by a pseudocapsule (arrows). A cluster of slightly enlarged nodes is present, some of them with the "fat ring sign" (* in B).

slide32.jpg

Retractile Mesenteritis

- Chronic and fulminant subgroup of sclerosing mesenteritis.
- Presence of one or more irregular fibrotic soft-tissue mesenteric masses with stellate appearance.
- The mesenteric mass sometimes shows calcifications and there may be encasement of the adjacent bowel loops and vascular structures.
- These imaging features overlap with those of carcinoid tumors, desmoid tumors and peritoneal carcinomatosis.

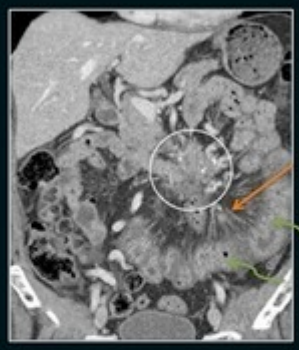

Patient with chronic abdominal pain.

Coronal reformatted contrast-enhanced CT image shows a partially calcified, fibrotic mass (circle) at the root of the jejunal mesentery. The jejunal mesenteric vessels appear engorged (arrow), and the wall of the affected portion of jejunum is thickened (curved arrows), probably due to obstruction of veins and lymphatics draining this bowel segment.

slide33.jpg

Mesenteric Adenitis

- Primary mesenteric adenitis is most frequent in children who present with right lower quadrant abdominal pain, fever and leucocytosis.
- On CT, the only finding is a cluster (more than three) of right-sided lymph nodes (usually larger than 5mm) in the small bowel mesentery or anterior to the psoas muscle, without an identifiable inflammatory condition.

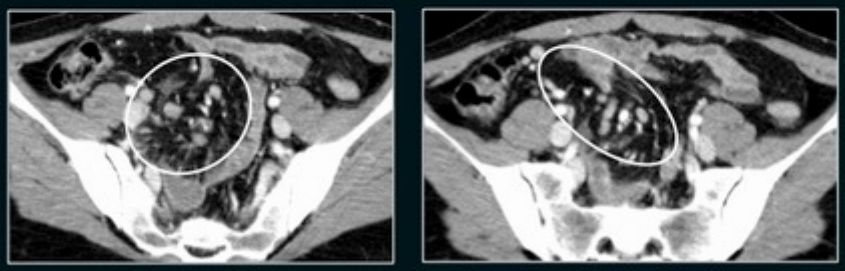

Young women with acute abdominal pain in the right lower quadrant and mild fever. Axial enhanced CT images show several enlarged mesenteric lymph nodes (circles), in the absence of other detectable abnormalities.

slide34.jpg

EDEMA

- Mesenteric edema is caused by many conditions: heart failure, hypoalbuminemia, liver cirrhosis, artery or venous thrombosis (portal and superior mesenteric vein, SMA) and vasculitic processes.
- In the systemic cause for mesenteric edema, the fluid infiltrates the SBM, causing attenuation of the mesenteric fat to increase diffusely. So, there is mesenteric haziness from the serosal surface of the intestine to the root of SBM with loss of the sharp interfaces between mesenteric vessels and fat.
- Ascitic fluid and subcutaneous tissue edema could be associated.

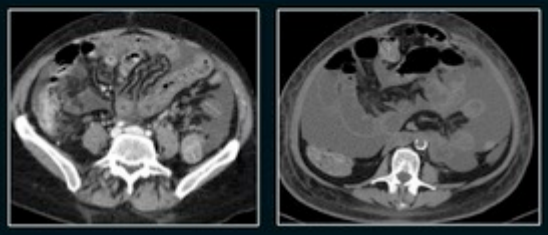

Two cases of heart failure with mesenteric haziness and ascites.

In the second patient there is also subcutaneous tissue edema.

slide35.jpg

MESENTERIC TUMORS AND TUMOR-LIKE LESIONS

- Mesenteric masses arise either from a proliferation of the intrinsic cell lines (primary tumors) or from metastatic invasion or from cellular proliferation in response to an infectious or inflammatory process.
- Primary tumors arising in the mesentery are rare. Their discovery is most often fortuitous or occurs during evaluation of vague non-specific abdominal symptoms.
- The wide diversity of different types of mesenteric masses is due to the multitude of cellular lines that compose the mesenteric structures: peritoneal surfaces, connective tissue, fatty tissue, lymphatic vessels, lymph nodes and blood vessels.
- Secondary tumors are relatively frequent as the mesentery is a frequent route of spread for malignant neoplasms through the peritoneal cavity and between the peritoneal spaces and the retroperitoneum.

slide36.jpg

Desmoid Tumor (Fibromatosis)

- Benign proliferation of fibrous tissue
- Rare: only 8% of desmoid tumors are localized to the mesentery
- Non-encapsulated
- Occurs sporadically, but common in patients with Gardner Syndrome (who have undergone abdominal surgery).
- Soft-tissue mass with well-demarcated or poorly defined borders and strands radiating into the adjacent mesenteric fat.
- Can infiltrate adjacent organs or grow into the abdominal wall musculature – locally aggressive.
- Isoattenuating relative to muscle with areas of low attenuation caused by necrosis (in larger lesions).

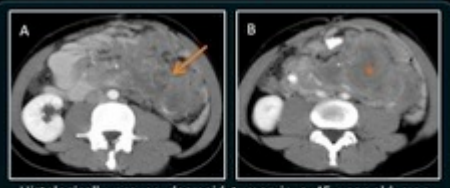

Histologically proven desmoid tumor in a 45 year-old man with insidious abdominal pain and history of familial adenomatous polyposis syndrome. (A and B) Axial contrast-enhanced CT images of the lower abdomen show a soft-tissue mass in the mesentery (arrow in A). The attenuation of the mass is similar to that of the psoas muscles. There are central areas of lower attenuation (* in B).

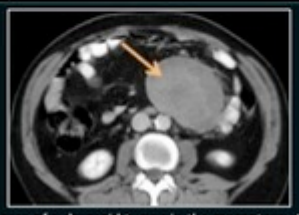

Another case of a desmoid tumor in the mesentery. Young man without history of familial adenomatous polyposis syndrome. There is a well defined soft tissue mass in the mesentery (arrow).

slide37.jpg

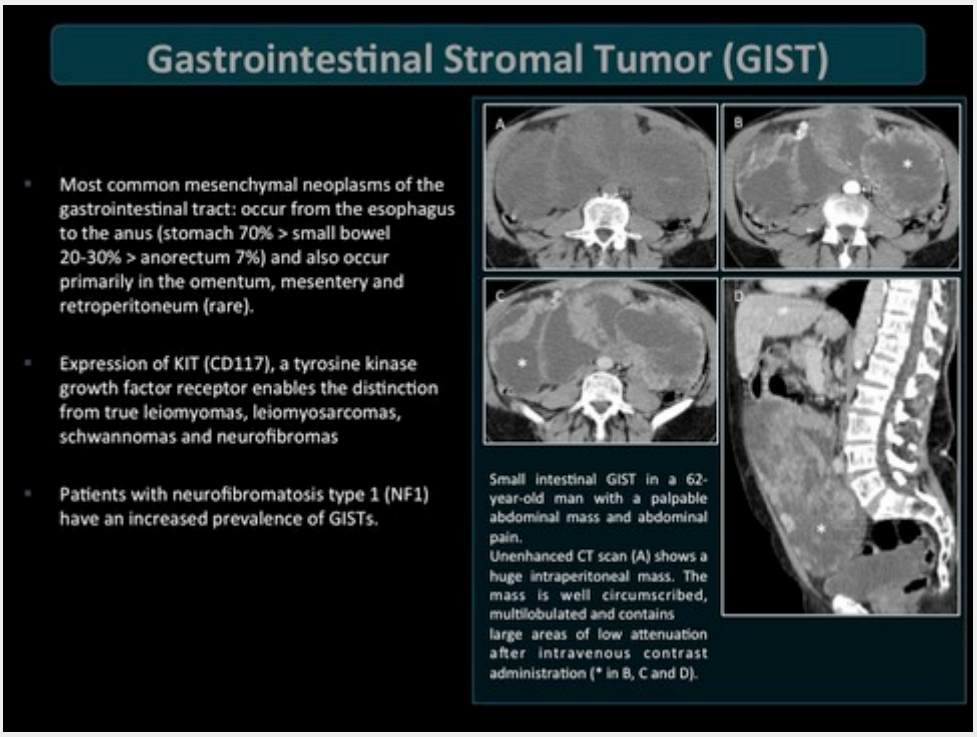

slide38.jpg

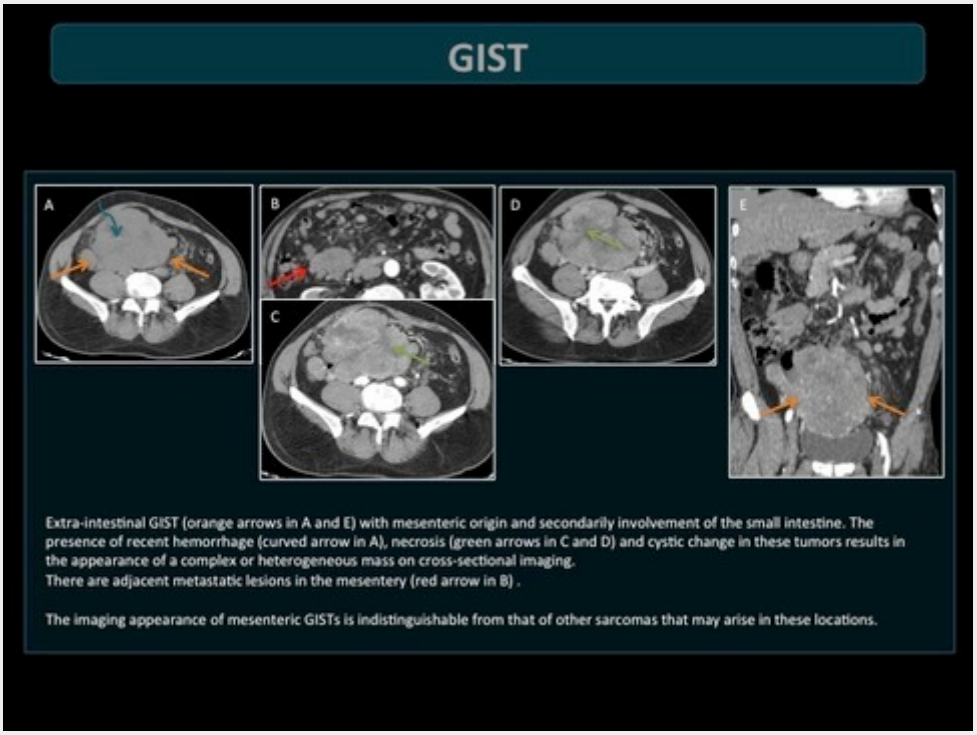

slide39.jpg

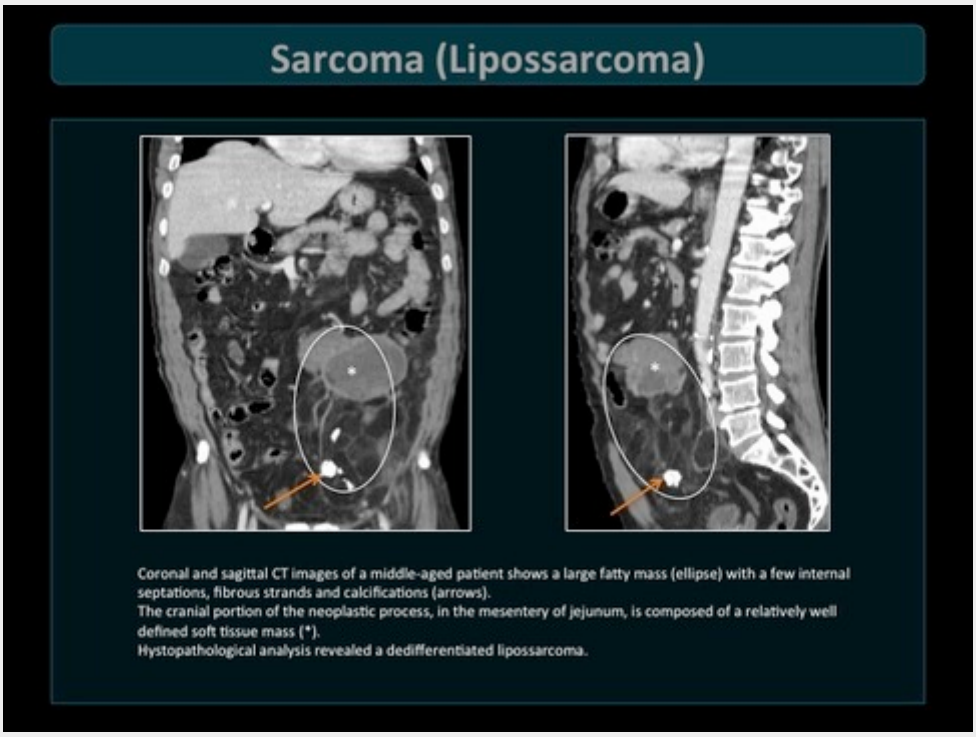

slide40.jpg

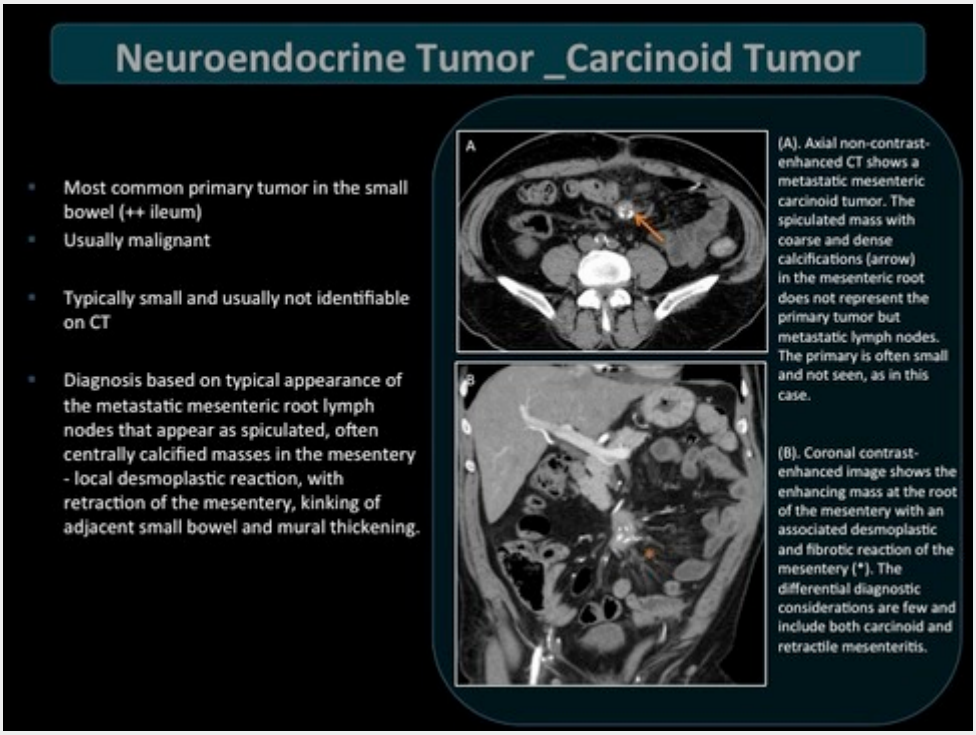

slide41.jpg

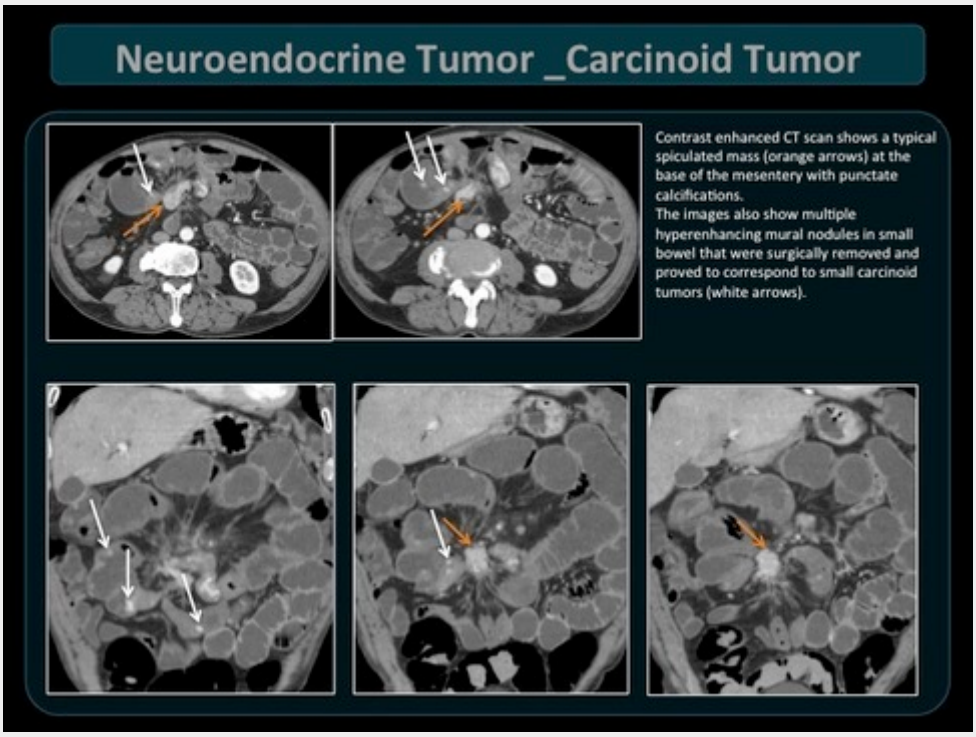

slide42.jpg

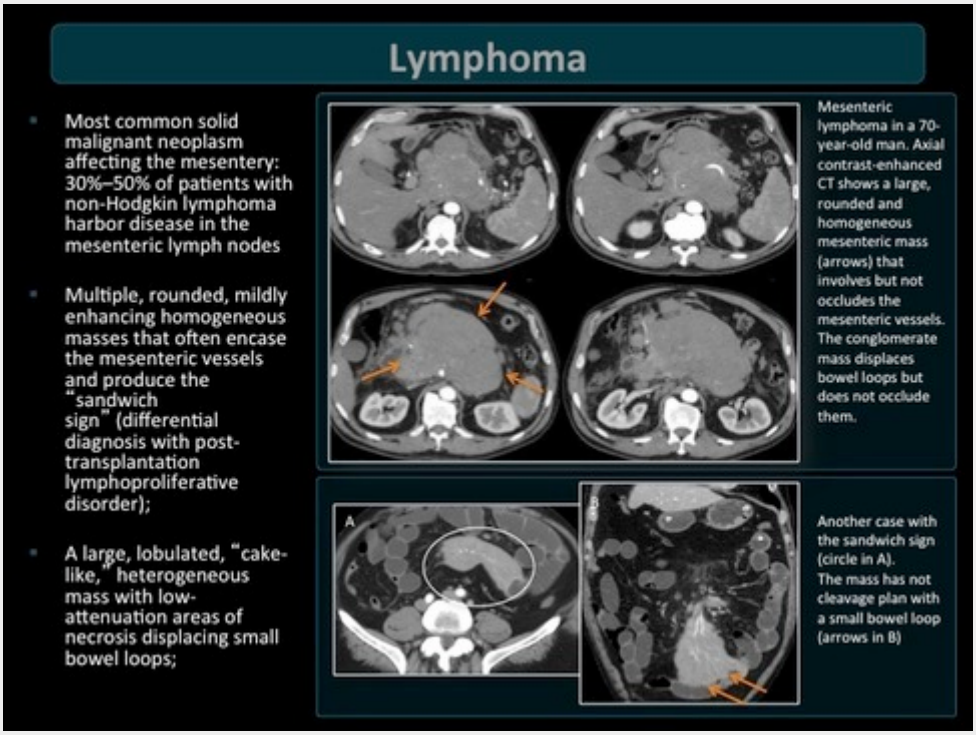

slide43.jpg

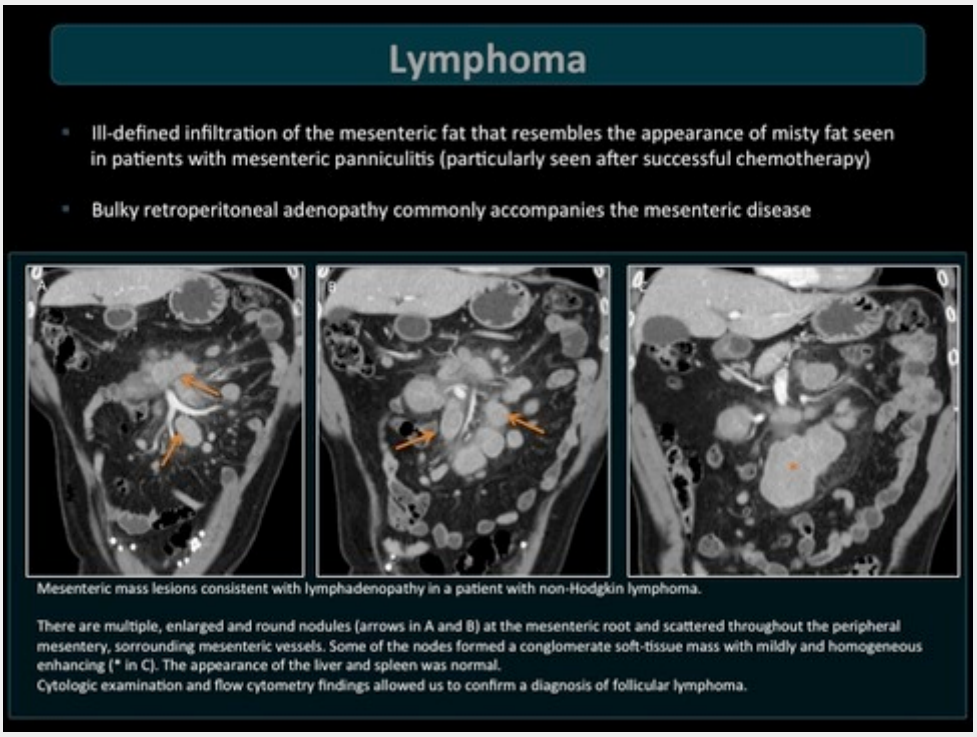

slide44.jpg

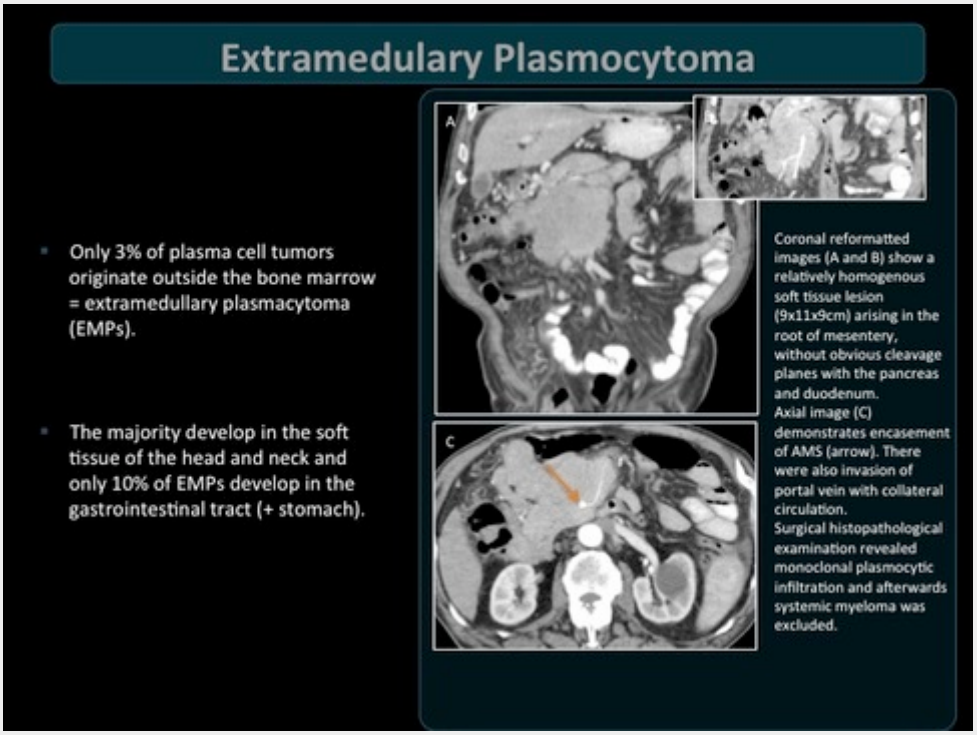

slide45.jpg

Castleman Disease

- Castleman disease or angiofollicular lymph node hyperplasia, is a rare, generally benign disease characterized by atypical proliferation of lymphocytes.
- Most often found in the mediastinum (67%) > neck (10-15%); abdomen and pelvis (10-15%).

- Most commonly manifests as a localized mass or masses (lymphadenopathy).
- Smaller tumors (<5 cm) display homogeneous contrast enhancement; larger tumors (>5 cm) show heterogeneous enhancement correlated with central necrosis and degeneration.
- Striking contrast enhancement of enlarged nodal masses at CT represents the only suggestive feature of this entity.

- Can display a variety of calcification patterns: punctate, coarse and peripheral.

- Increased risk of lymphoma

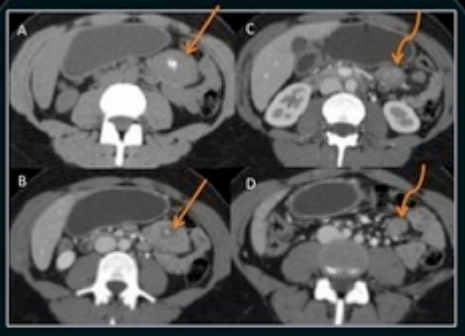

Axial unenhanced CT image demonstrating a well-defined mesenteric mass with punctate calcifications (arrow in A).

After intravenous contrast administration there was slight heterogenous enhancement (low attenuation central area) (arrow in B).
There were two other small rounded nodules, adjacent to the previous mass described (curved arrows in C and D).

slide46.jpg

Mesenteric Cyst

- Generic descriptive term for cystic mass arising in mesentery or omentum.
- May refer to cystic lymphangioma unless otherwise specified.

- CT appearance is that of a circumscribed cystic mass in mesentery or retroperitoneum with variable density and non-enhancing content.
- Water-density (near 0 HU), chylous (< -20 HU), rarely hemorrhagic.
- ± fine calcifications along cyst wall, with or without septa.

- Should be differentiated from loculated ascites, gastrointestinal duplication cysts, pancreatic pseudocyst, cystic pancreatic tumor and peritoneal inclusion cyst.

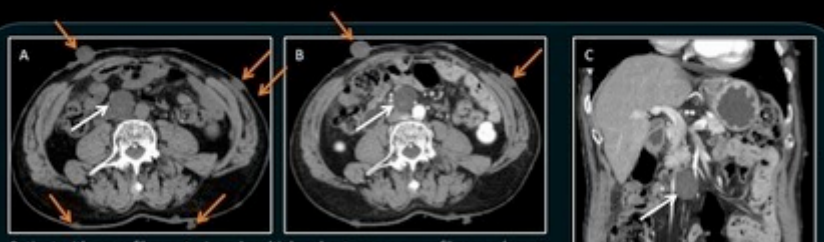

Patient with neurofibromatosis and multiple subcutaneous neurofibromas (orange arrows).
CT shows a near-water-density mass in the mesentery (white arrow in A) without contrast enhancement (B and C), that correspond to a lymphoepithelial cyst.

slide47.jpg

Acessory spleen

- One or more small splenic masses may develop in one of the peritoneal folds early in fetal life.
- An accessory spleen is present in about 10% of individuals, commonly situated near the hilum of the spleen or adjacent to the tail of the pancreas.

A 3,5cm well-defined round mass (orange arrows) was incidentally discovered in a 35 year-old man. Its attenuation is identical to that of splenic tissue, both before (A) and after administration of contrast medium (B – arterial phase; C – portal phase; D – late phase).

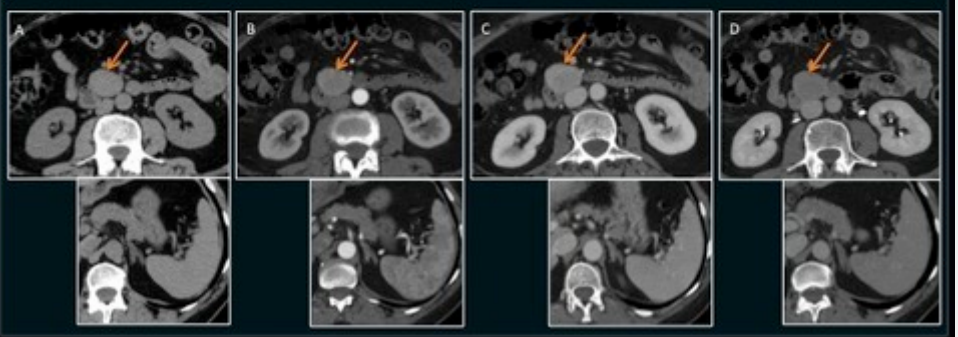

slide48.jpg

Malignant Peritoneal Mesothelioma

- Rare neoplasm with a rapidly fatal course. Half of the cases are related to asbestos exposure
- Solid, enhancing soft-tissue mass within the mesentery, omentum, or peritoneum; infiltrating mass; or multiple small nodules.
- 3 types: - "dry-painful" type: multiple small peritoneal masses or a single dominant mass. Little or no ascites is identified.
- - "wet" type: ascites associated with widespread small nodules and plaques, without a dominant solid mass.
  - combination of these clinical subtypes, in which patients may present with pain and ascites
- It has a tendency to spread along serosal surfaces and for direct invasion of both solid and hollow intra-abdominal organs (+ colon and liver).

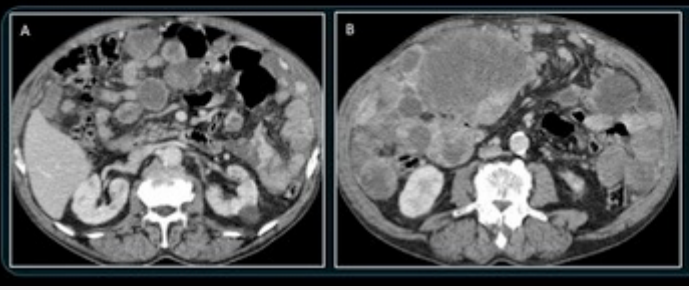

Axial contrast-enhanced CT scan shows "dry-painful" type of malignant peritoneal mesothelioma in a 73-year-old man.
There is a dominant mass in the right abdominal quadrants and other multiple small peritoneal, omental and mesenteric metastases. Small ascites was identified in the pelvis.

slide49.jpg

Secondary Involvement : Infectious and Inflammatory, Neoplastic and Tumor-Like lesions

- The pathologic conditions that may secondarily affect the peritoneum and peritoneal cavity, the mesenteries and omentum, can be categorized into three broad groups: metastatic neoplasms, infectious and inflammatory lesions, and miscellaneous tumors and tumorlike lesions.
- The root of the mesentery is a connecting way between several intraperitoneal compartments and the retroperitoneum, namely lesser sac, supramesocolic compartment, both inframesocolic compartments and inferior retroperitoneum.
- There are different ways of involvement:
  - Direct extension
  - Extension along ligaments and peritoneal folds
  - Neural plexus extension
  - Lymphatic vessel extension.
- Closely related to retroperitoneal pathology because there is not a clear limit between the retroperitoneum and the mesentery.

slide50.jpg

Mesenteric Metastases

- Metastases from carcinomas of the colon ovarian, breast, lung and melanoma can spread to mesenteric lymph nodes.
- The most common malignant process in the peritoneal cavity.
- However, the degree of nodal enlargement seen in mesenteric metastatic disease is less pronounced than that seen in mesenteric lymphoma.
- The distribution of involved nodes is comparatively more localized in metastatic disease.

Metastatic melanoma in a 55-year-old man. Axial post-contrast CT image demonstrates several enhancing masses in the small bowel mesentery (arrows) that represented mesenteric implants of melanoma.
The small intestine and its mesentery are the most common site of gastrointestinal metastases from melanoma.

slide51.jpg

Carcinomatosis

- Metastatic tumoral seeding of peritoneal surface, peritoneal ligaments, omentum, and mesentery.
- Primary intraperitoneal seeding occurs most commonly from gastrointestinal (stomach and colon) and ovarian malignancies.
- Can occur as:
- Peritoneal deposits: Multiple nodules or plaques on peritoneal surface (+ pouch of Douglas, Morrison pouch and right subphrenic space).
- Omental cake: Large conglomerate soft tissue mass on peritoneum/omentum.
- Mesenteric infiltration: Infiltration of mesenteric leaves with thickening; may give "sunburst" appearance.

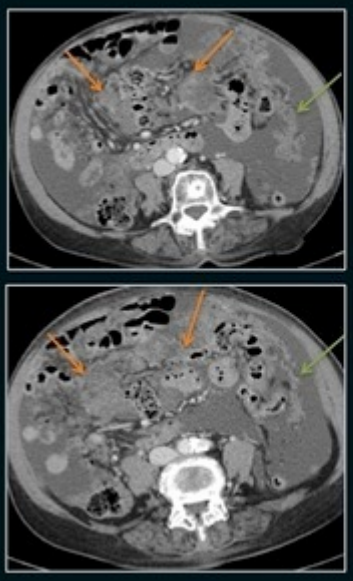

77-year-old women with abdominal enlargement and diffuse abdominal pain.
Axial contrast-enhanced CT image of the mid-abdomen shows extensive and diffuse soft-tissue infiltration of the mesenteric fat (orange arrows) – stellate appearance.
Omental caking and ascites are also present (green arrows).

slide52.jpg

Peritoneal Lymphomatosis

- Peritoneal lymphomatosis refers to multiple intra-abdominal organ infiltration or disseminated peritoneal lymphoma.
- Lymphoma can occur at any site in the body, but diffuse and extensive involvement of the peritoneal cavity and presentation as peritoneal carcinomatosis is very rare.
- On CT scan, patterns of tumor involvement of mesentery, omentum and peritoneum are indistinguishable from those seen in peritoneal carcinomatosis or tuberculous peritonitis.

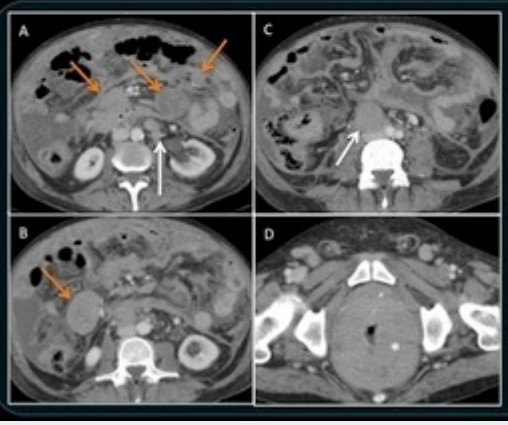

Peritoneal lymphomatosis in a 71-year-old man with abdominal pain and distention for 15 days.
CT scan shows ascites and innumerable seeding nodules in the peritoneum, omentum and mesentery (orange arrows in A and B).
Multiple enlarged lymph nodes with conglomeration are seen in the retroperitoneal spaces (white arrows in A and C).
There is also extensive and diffuse soft-tissue infiltration of the mesenteric fat.
The wall of the rectum was very thickened due to involvement by the neoplasm (* in D).

slide53.jpg

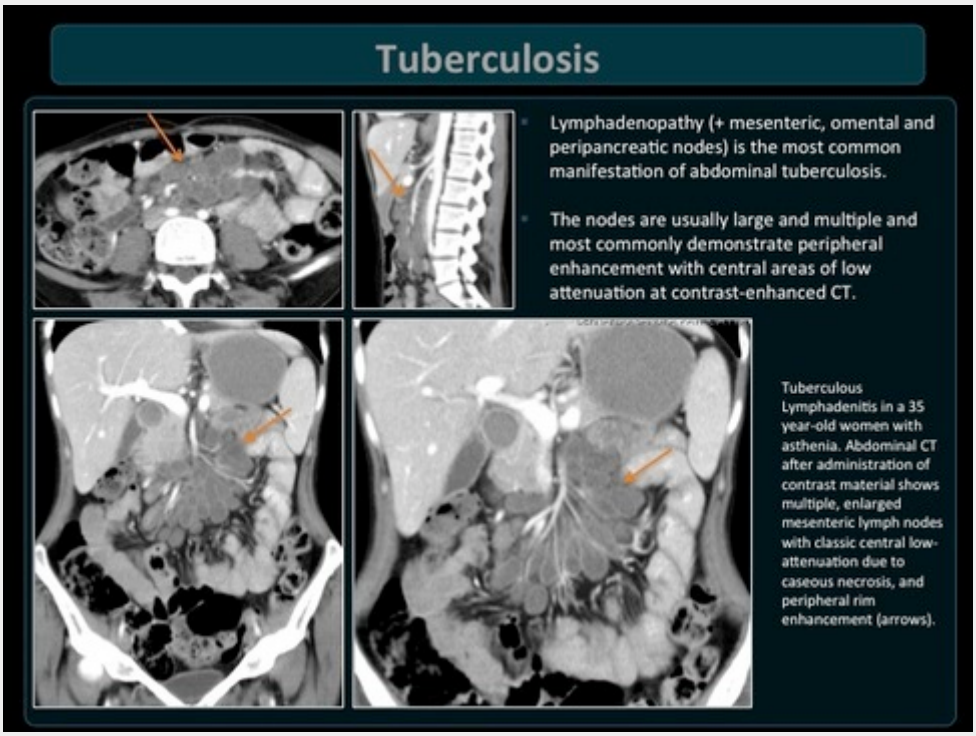

slide54.jpg

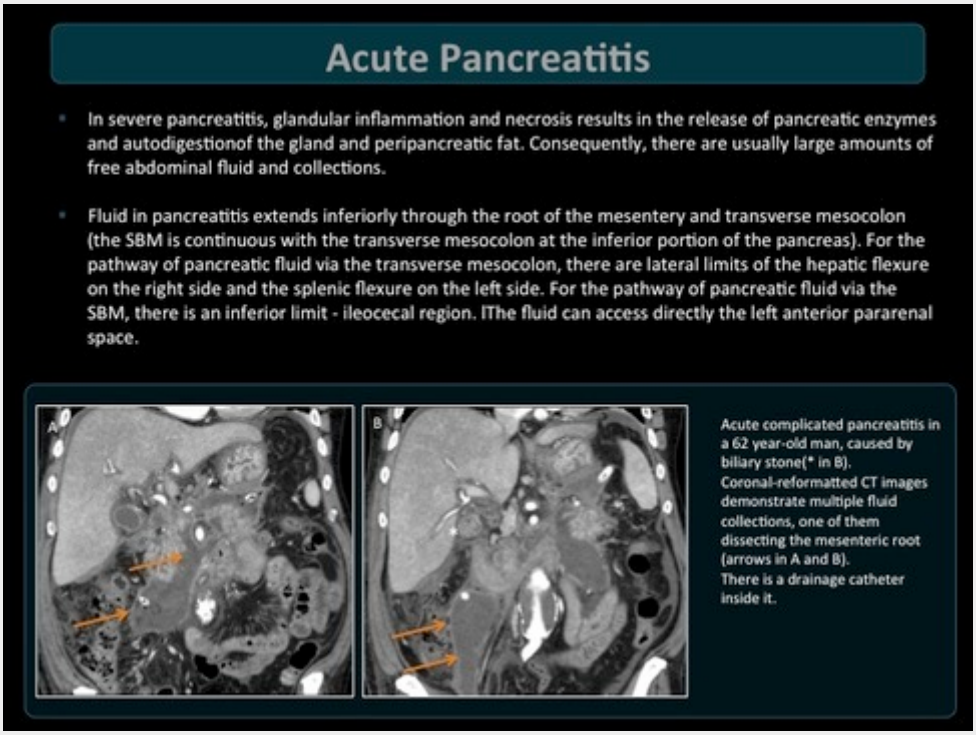

slide55.jpg

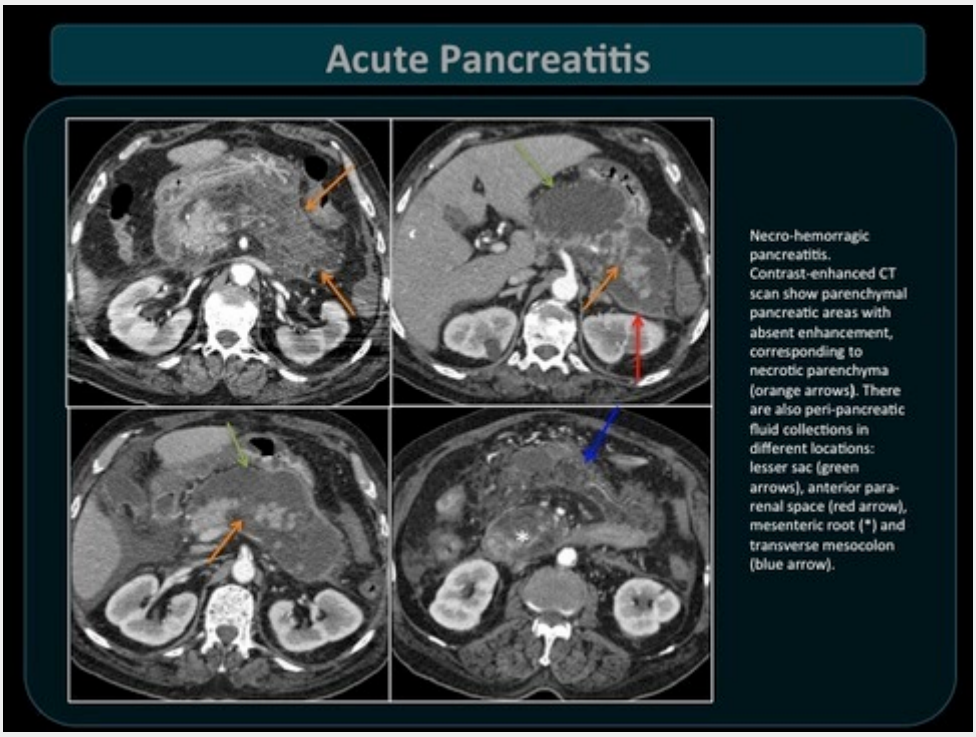

slide56.jpg

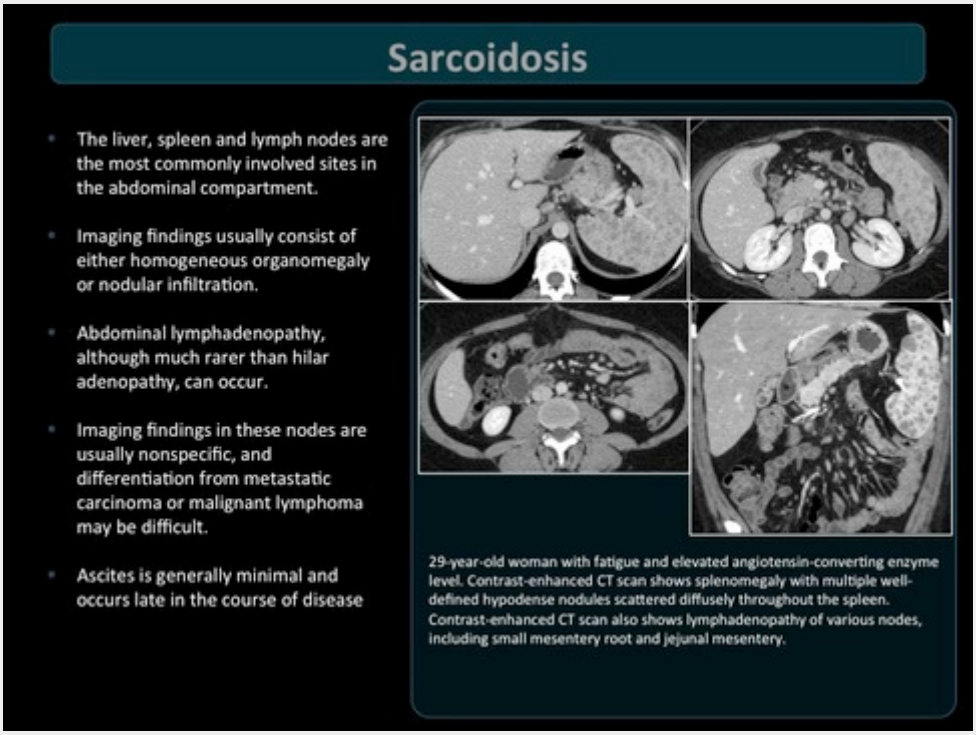

4. Conclusion

Conclusion

slide57.jpg

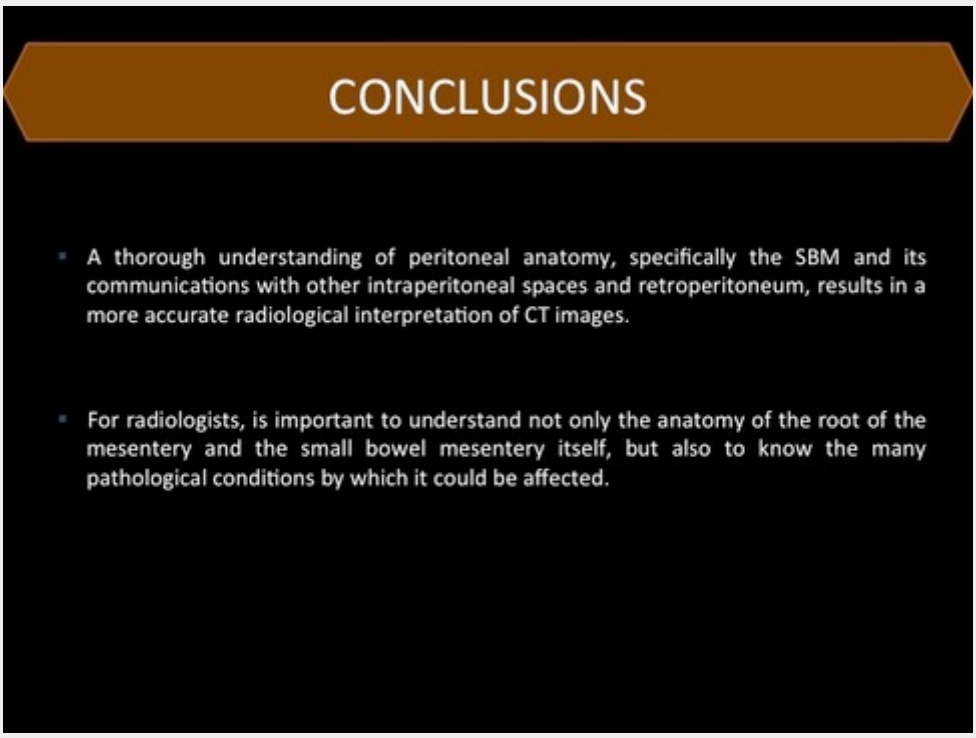

5. References

slide58.jpg

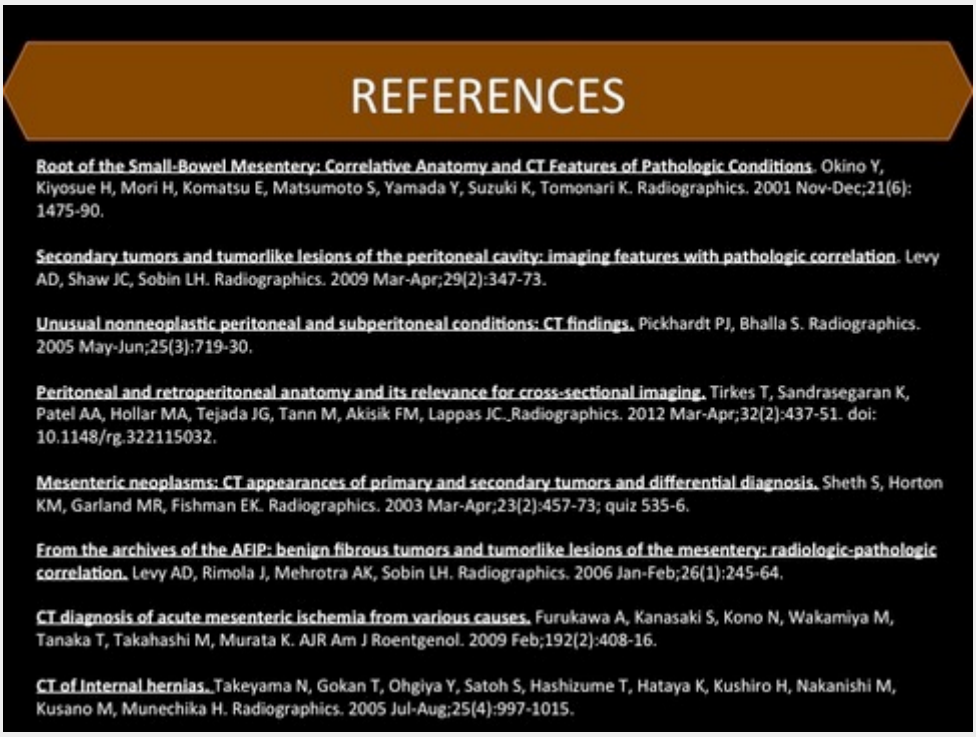

6. Author Information

slide59.jpg

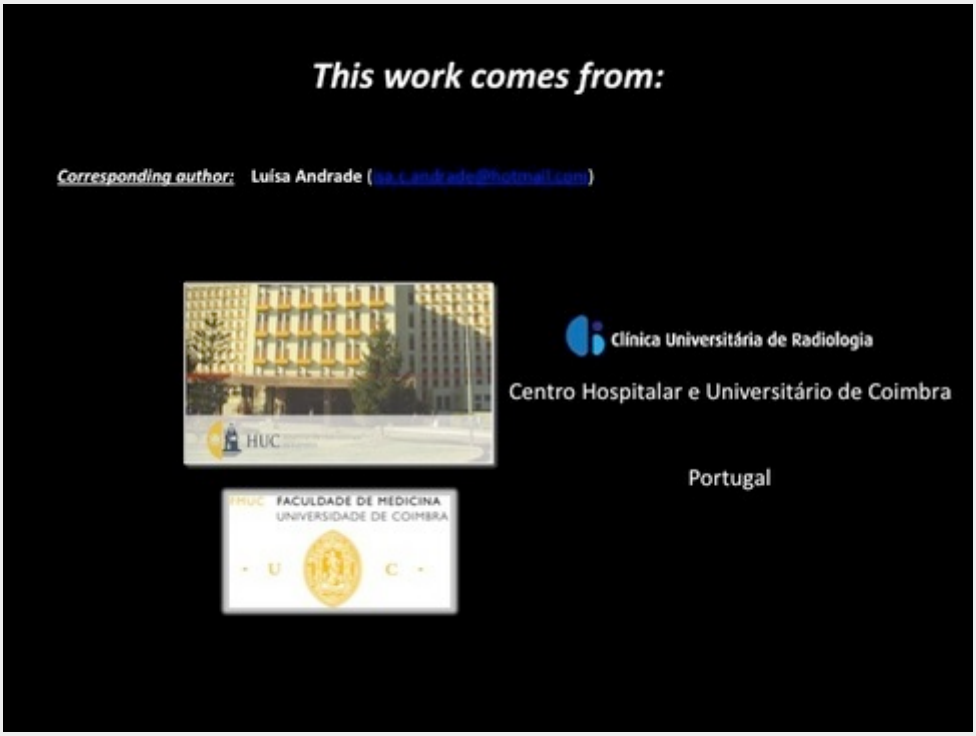

7. Mediafiles

slide01.jpg

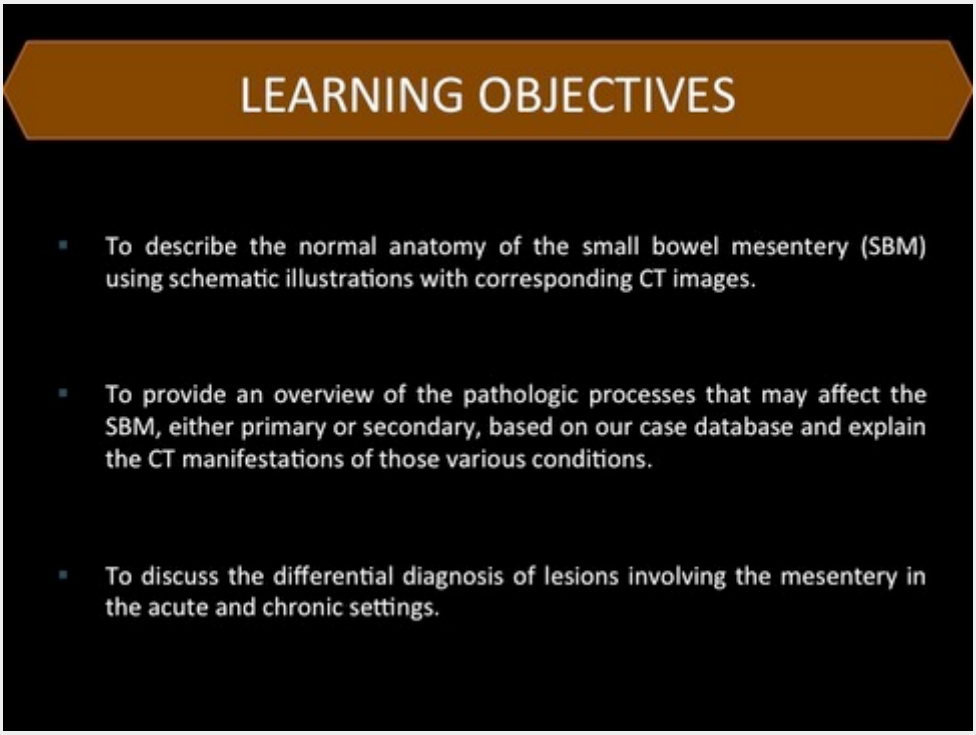

slide02.jpg

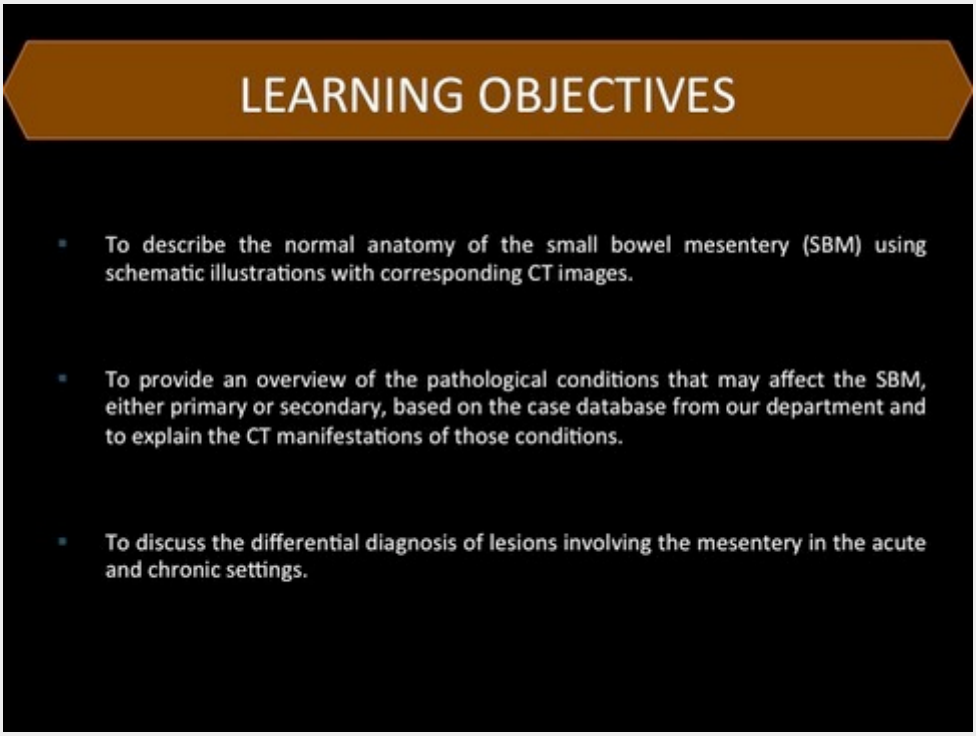

slide03.jpg

BACKGROUND

- The root of the small bowel mesentery is located deep in the abdomen, where peritoneal and retroperitoneal pathological conditions may overlap.
- It is closely related to other intraperitoneal spaces (supra and inframesocolic) and the retroperitoneum. As such it is a common route of spread of patological conditions, namely infections and neoplastic processes.

slide04.jpg

REVIEWING ANATOMY

PERITONEAL CAVITY

- Potential space in abdomen between visceral and parietal peritoneum, usually containing only a small amount of peritoneal fluid (for lubrication).
- Divided in greater sac and lesser sac (omental bursa) that communicates with greater sac via epiploic foramen (of Winslow).
- The peritoneum is a serous membrane that consists of two layers which are continuous with each other. One parietal, attached to the posterior abdominal wall and one visceral, lining the external surface of viscera.
- The parietal peritoneum has reflections or folds that fix intraperitoneal organs to the posterior abdominal wall, forming the anterior limits of the retroperitoneum. The mesenteric root corresponds to the attachment of one of these folds.

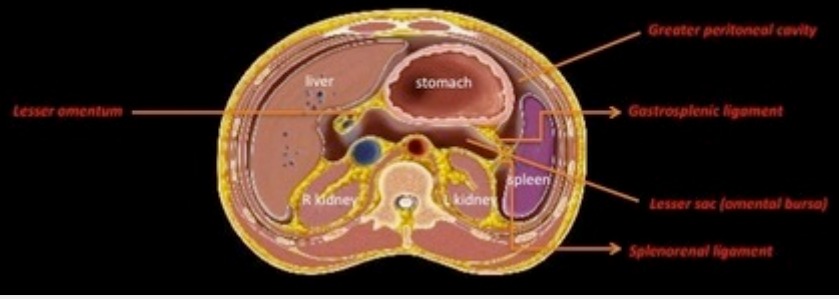

slide05.jpg

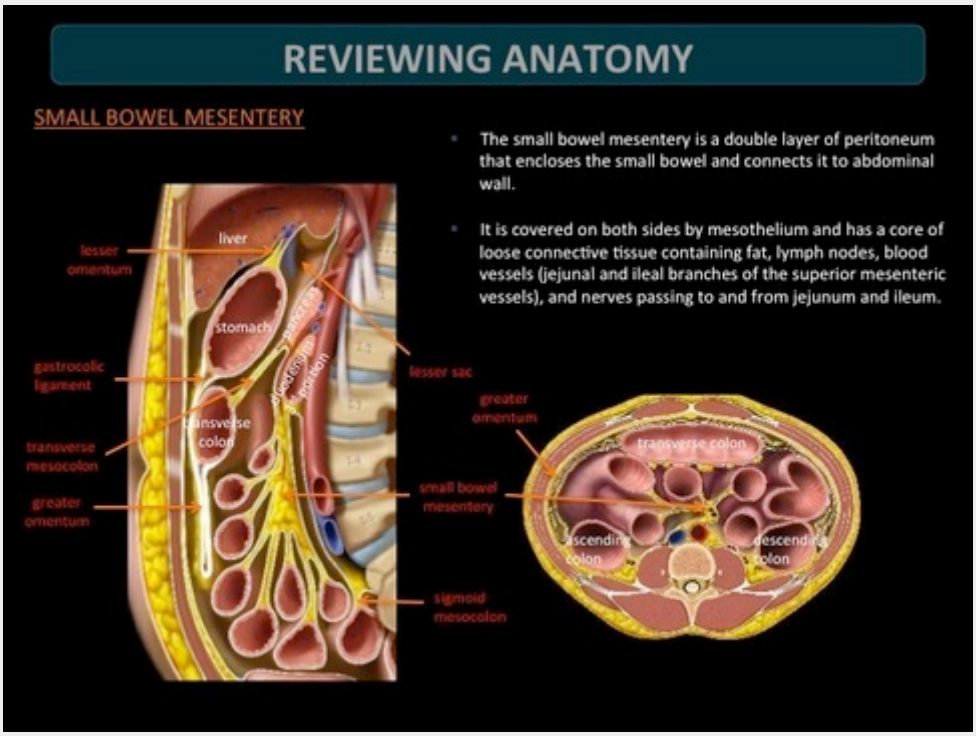

slide06.jpg

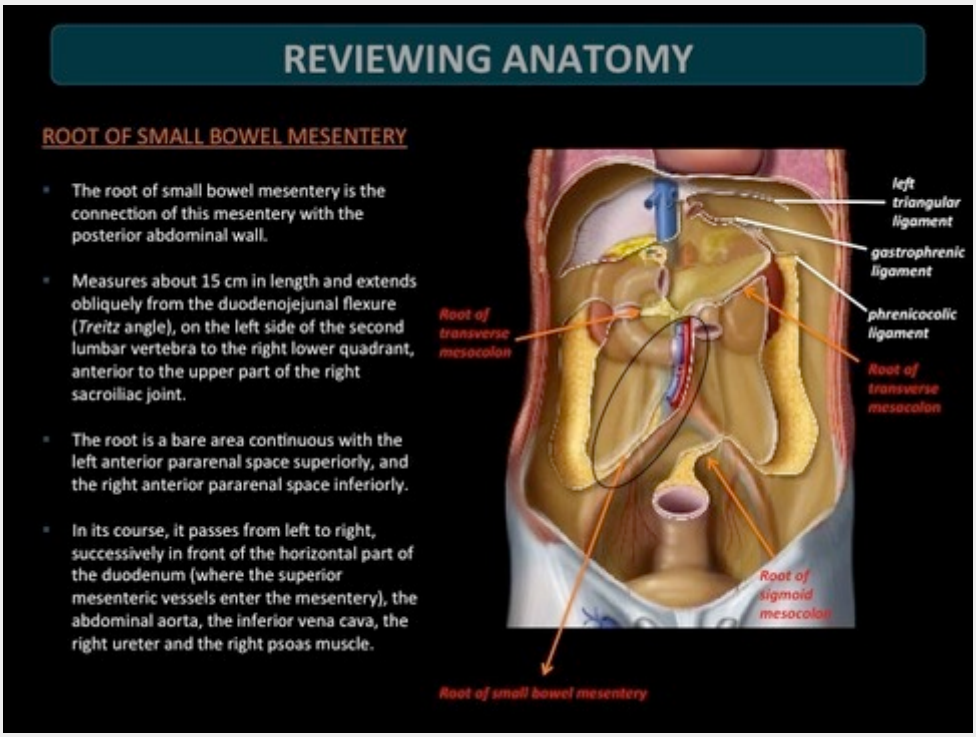

slide07.jpg

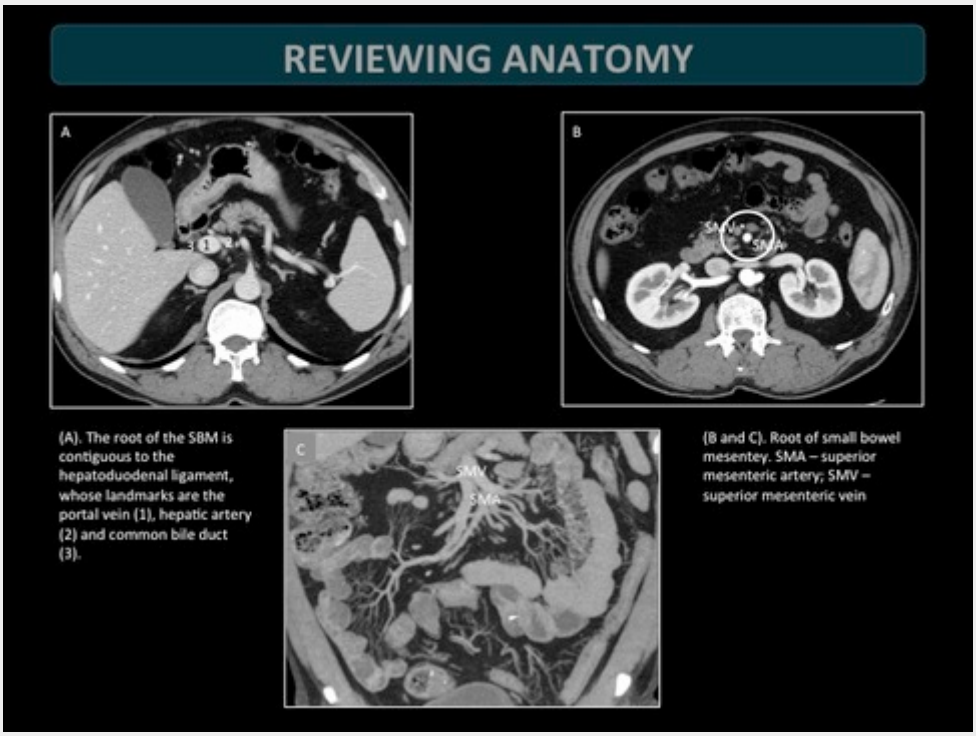

slide08.jpg

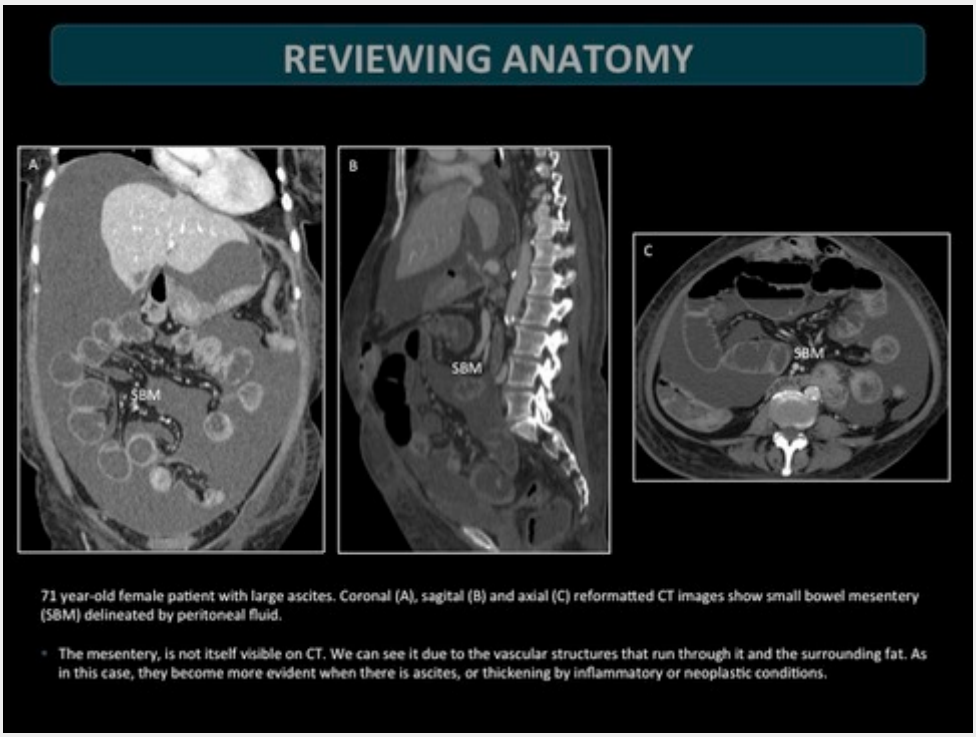

slide09.jpg

IMAGING FINDINGS

Pictorial review of primary small bowel mesentery pathology (such as rotation abnormalities, vascular disorders, inflammation and edematous conditions, trauma and tumors) as well as secondary pathology (extension of inflammatory and neoplastic conditions).

slide10.jpg

ANOMALIES

- At 6 weeks gestation, the intestinal tract is a continuous and tubular structure that is divided into the foregut (supplied by the celiac artery), midgut (supplied by the superior mesenteric artery – SMA) and the hindgut (supplied mainly by the inferior mesenteric artery – IMA).
- Intestinal malrotation can be broadly defined as any deviation from the normal 270° counterclockwise rotation of the midgut during embryologic development.
- There are 3 subtypes of rotation anomalies: non-rotation, incomplete rotation and reversed rotation (very rare).
- Malrotation results not only in the malposition of the bowel, but also in the malfixation of the mesentery. The normally broad mesenteric attachment is shortened to a narrow pedicle that predisposes the patient to small bowel volvulus.
- Internal hernia related to abnormal peritoneal fibrous bands (of Ladd) that attach to the right colon is another complication of malrotation seen in adults.

slide11.jpg

Rotation Anomalies of the Midgut

Nonrotation

- The midgut returns to the peritoneal cavity after rotating only 180º instead of the normal 270º.
- The small intestine is on the right side of the abdomen and the colon on the left side. The ileum crosses the midline from the right to the left to enter the cecum. The SMA is on the right side of the SMV.
- Most common anomaly and generally asymptomatic but increased risk for volvulus.

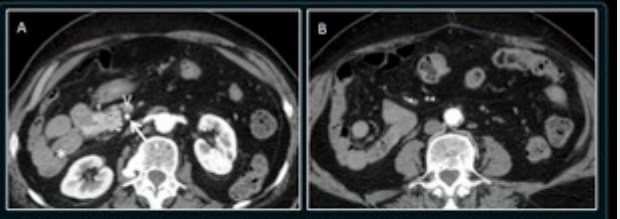

(A). 72-year-old woman with right abdominal pain. Axial contrast-enhanced CT scan shows inverted relationship between superior mesenteric artery (arrow) and superior mesenteric vein (v). Note the duodenojejunal flexure on the right (*).
(B). CT scan obtained through mid abdomen shows characteristic appearance of small bowel on right and colon on left.

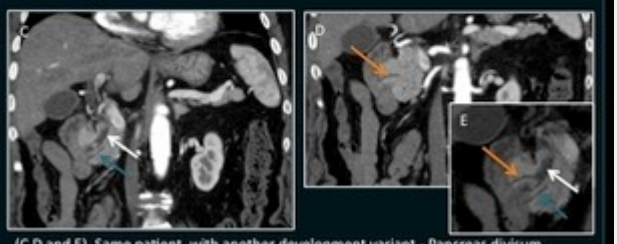

(C,D and E). Same patient, with another development variant - Pancreas divisum. Common bile duct (CBD) (white arrow); Dorsal duct (Santorini) (orange arrow); Small ventral duct (Wirsung) (blue arrow). CBD stone and associated obstructive cholangitis.

slide12.jpg

Rotation Anomalies of the Midgut

Incomplete Rotation

- Failure of the midgut loop to complete the final 90º of rotation.
- The cecum lies just inferior to the pylorus of the stomach and is fixed to the posterior abdominal wall by peritoneal bands passing over the duodenum.
- Increased risk of duodenal obstruction due to these bands or volvulus of the intestine.

Reversed Rotation

- Very rare
- The midgut rotates in a clockwise rather than a counterclockwise direction.
- The duodenum lies anterior and the transverse colon lies posterior to the SMA.
- Increased risk of obstruction of the transverse colon.

slide13.jpg

Internal Hernia

Paraduodenal Hernia

- Most common type of internal abdominal hernias; frequency - left side 3: 1 right side
- Result from congenital abnormalities in mesenteric peritoneal fixation.
- Frequently symptomatic; partial or complete obstruction of the small intestine (50%)

Left paraduodenal hernia (LPDH)

- Develops through a peritoneal defect (the paraduodenal or Landzert fossa) situated at the duodenojejunal junction (confluent zone of the descending mesocolon, transverse mesocolon, and SBM) and extends behind the descending mesocolon and the left portion of the transverse mesocolon.
- IMV it is the most important landmark of the duodenojejunal junction.

slide14.jpg

Left Paraduodenal Hernia

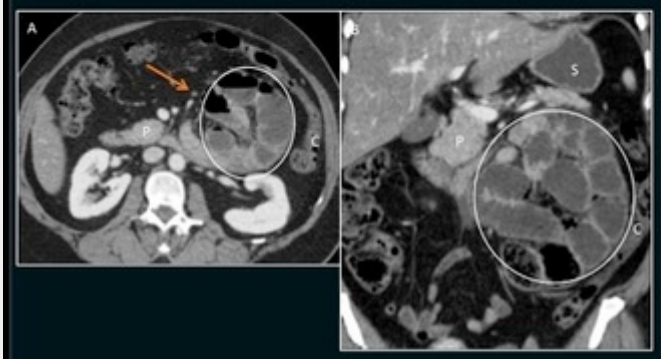

LPDH in a 50-year-old man with acute, intermittent epigastric pain. Contrast-enhanced CT scan of the upper abdomen shows a sac-like mass of dilated jejunal loops (circle) between the pancreatic head (P) and stomach (S in B). The descending mesocolon (C) and stomach are displaced laterally.
The inferior mesenteric vein is a landmark for the inferior mesocolon, which is located at the anteromedial border of the encapsulated jejunal loops.

- CT can demonstrate an encapsulated bowel loop that displaces the inferior mesenteric vein anteriorly, suggesting that the trapped loop is located behind the descending mesocolon.
- The trapped small-bowel loops are dilated; if they are strangulated, there is congestion of the SBM.

slide15.jpg

Right Paraduodenal Hernia

Right paraduodenal hernia (RPDH)

- Involves the mesentericoparietal fossa of Waldeyer, located just behind the root of the SBM.
- The SMA and SMV run along the free edge of the right paraduodenal hernia sac.
- Most frequent in nonrotation of the small intestine.

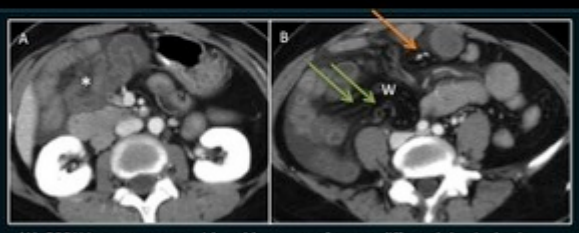

(A). RPDH in a young man with sudden onset of severe diffuse abdominal pain. Contrast-enhanced CT scan shows a sac-like mass of fluid-filled small bowel loops (*), most of which were jejunal and proximal ileal loops.
(B). The encapsulated bowel loops herniated through the fossa of Waldeyer (w), which is located behind the superior mesenteric artery (orange arrow) just below the transverse portion of the duodenum. The SMA is displaced anteriorly by the entrapped bowel loops and there is dilated and converging vessels (green arrows) in the mesentery.

- The superior mesenteric artery and right colic vein are located at the anterior-medial border of the encapsulated small bowel loops and are a landmark for right PDH.

slide16.jpg

Transmesenteric Hernia

- Transmesenteric (across small bowel mesentery) and transmesocolic hernias account for 8% of all internal hernias.
- Mechanical small bowel obstruction (SBO) is a common complication of these hernias.

- The bowel mesenteric defect itself is not visualized.
- Clustering of small bowel loops in association with proximal small bowel dilatation, with a transition zone to a normal or collapsed intestine.
- Abnormalities of the mesenteric vessels: the mesenteric vascular pedicle is characteristically engorged, stretched, and crowded; converging mesenteric vessels are located at the entrance of the hernial sac and there is displacement of the main mesenteric trunk.

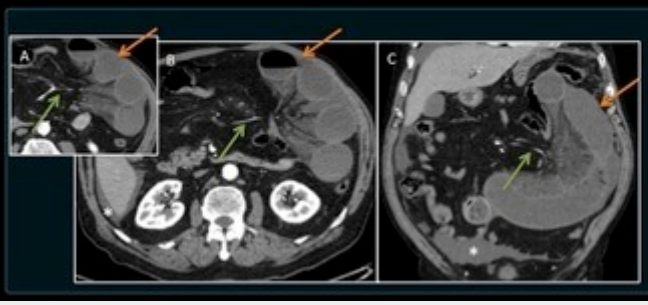

74 year-old man with SBO due to internal transmesenteric hernia.

Contrast-enhanced CT scan shows multiple dilated and fluid-filled loops of small bowel with air-fluid levels (orange arrows). There are stretched and converging vessels at the hernial orifice (green arrows) and ascitic fluid in the right iliac fossa and perihepatic (*).

As shown, this internal hernia causing SBO lead to focal segmental ischemia of the herniated small bowel loops.

slide17.jpg

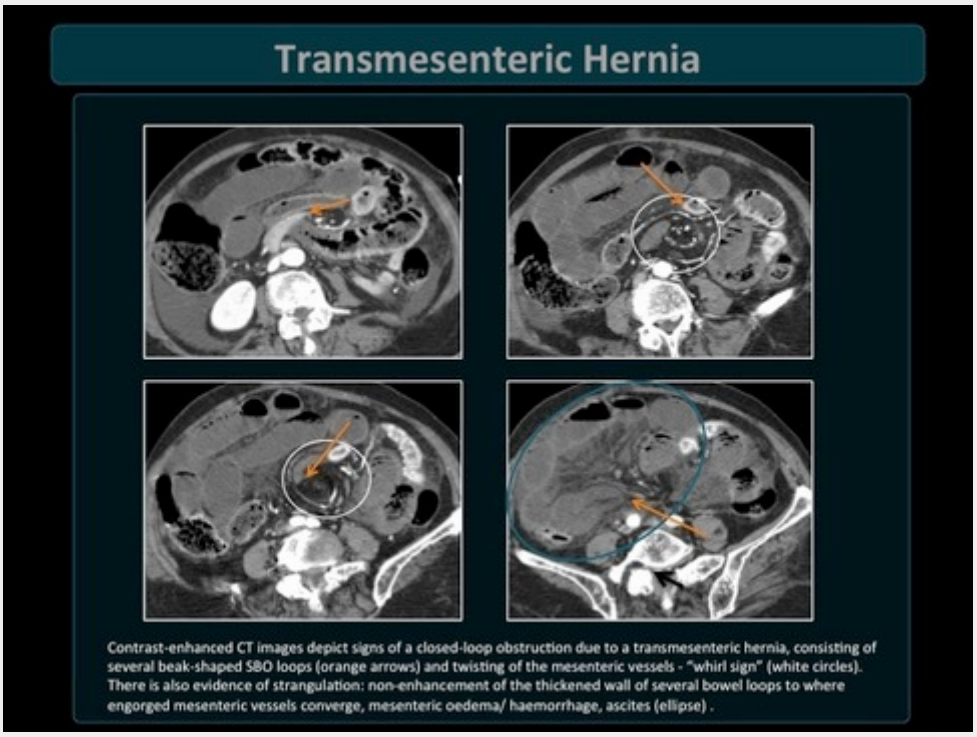

slide18.jpg

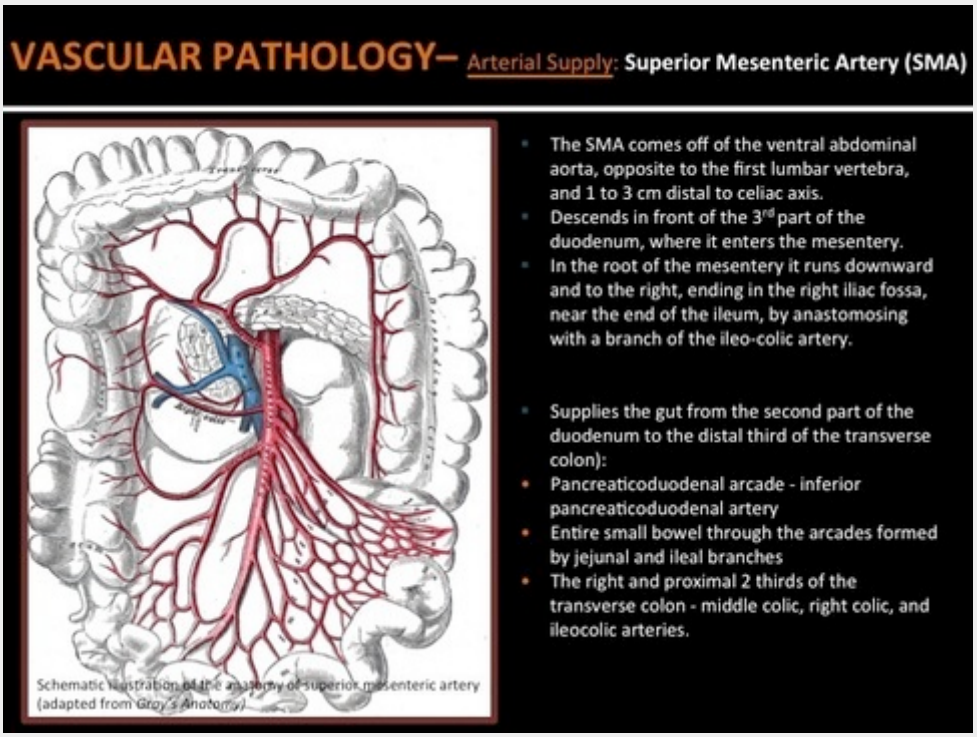

slide19.jpg

VASCULAR PATHOLOGY – Venous Drainage

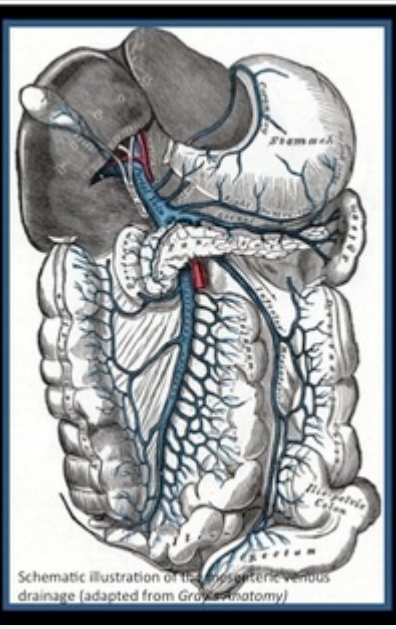

Schematic illustration of the mesenteric venous drainage (adapted from *Gray's Anatomy*)

- The mesenteric venous blood is drained by the portal vein, which is formed by the confluence of splenic vein and superior mesenteric vein (SMV).
- The mesenteric veins run parallel to the corresponding arteries.
- The inferior mesenteric vein receives supply from the left colic, sigmoid and superior rectal veins. It joins the splenic vein before its confluence with the SMV.
- The SMV receives the duodenal, pancreatic, right gastroepiploic, jejunal, ileal, right colic, and middle colic veins. The coronary veins (right and left gastric) drain directly into the portal vein.

slide20.jpg

Vascular Pathology – MESENTERIC ISCHEMIA

- Bowel injury during mesenteric ischemia is mediated by the injury of the tissue resulting from interruption of blood flow and by reperfusion which causes increased vascular and epithelial permeability with leakage of fluid into the bowel lumen, bacterial translocation and decreased intestinal blood flow.
- Ischemic Bowel Disease (IBD) can be acute or chronic and can range from reversible to transmural infarction with necrosis, intestinal bleeding and perforation, abscess formation and peritonitis.

MDCT – Evaluation of suspected Mesenteric Ischemia: BOWEL WALL
MESENTERIC VESSELS

slide21.jpg

ACUTE MESENTERIC ISCHEMIA

- **Arterial Occlusion**

- *Embolism* (50%): arrhythmias; valvular disease; myocardial infarction; cardiac aneurysm; aortic atherosclerotic disease; iatrogenic

- *Thrombosis* (10%): atherosclerotic disease; vasculitis; fibromuscular displasia; trauma; dissection

- **Venous Thrombosis** (10%): hypercoagulable states; sepsis; malignancy; portal hypertension; compression; pregnancy; surgery and trauma

- **Non-Occlusive Mesenteric Ischemia** (25%): heart failure; cardiac bypass; sepsis; systemic hypotension; burns; pancreatitis

- **Focal Segmental Ischemia** (extravascular) (5%): bowel obstruction; malignancy; surgery; radiation; vessel injury

slide22.jpg

ACUTE MESENTERIC ISCHEMIA – SMA Occlusion

- Hypodense *filling defect* of the arterial lumen

- *Decreased bowel wall attenuation* (submucosal edema and inflammation) or, less commonly, increased due to submucosal hemorrhage
- *Lack of bowel enhancement* or increased, delayed and persistent enhancement due to hyperemia (= good prognosis)

- *Very thin small bowel wall* (arterial occlusions) vs. circumferential bowel wall thickening (most common in venous occlusions)

- Transmural infarction: Intramural gas – *Pneumatosis Intestinalis; mesenteric and portal venous gas; pneumoperitoneum* (perforation of an infarcted bowel segment)

- *Mesenteric fat stranding* and *ascites* (more pronounced in venous occlusion)
- *Bowel dilatation* with fluid filled bowel loops

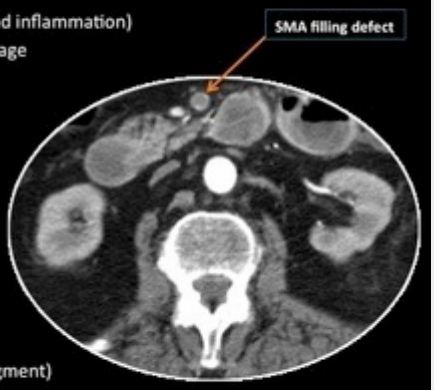

slide23.jpg

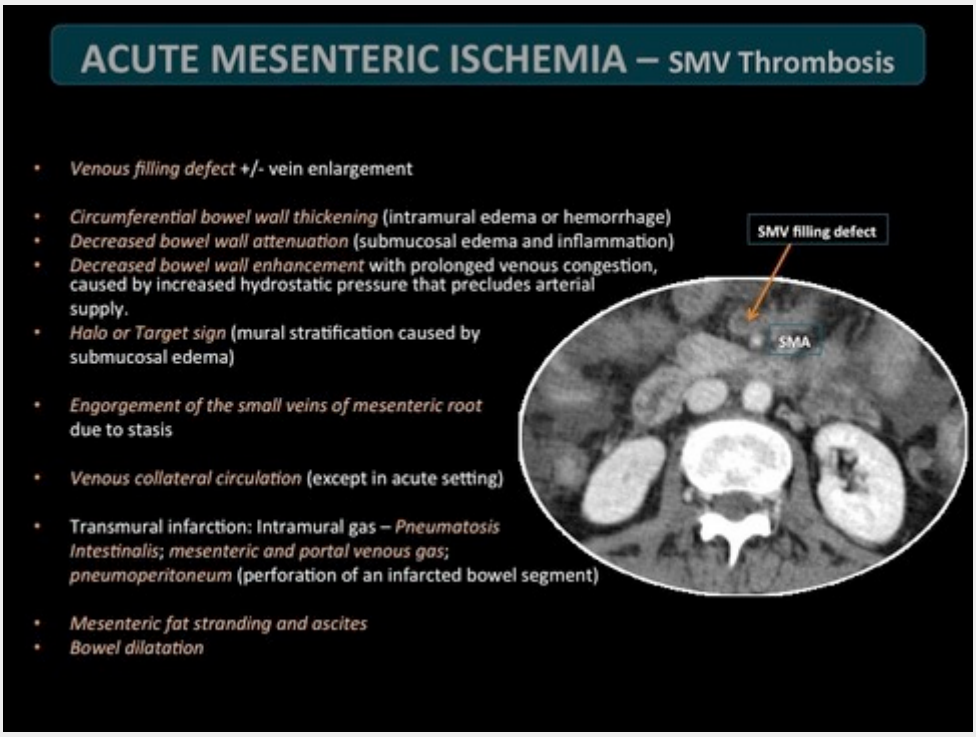

slide24.jpg

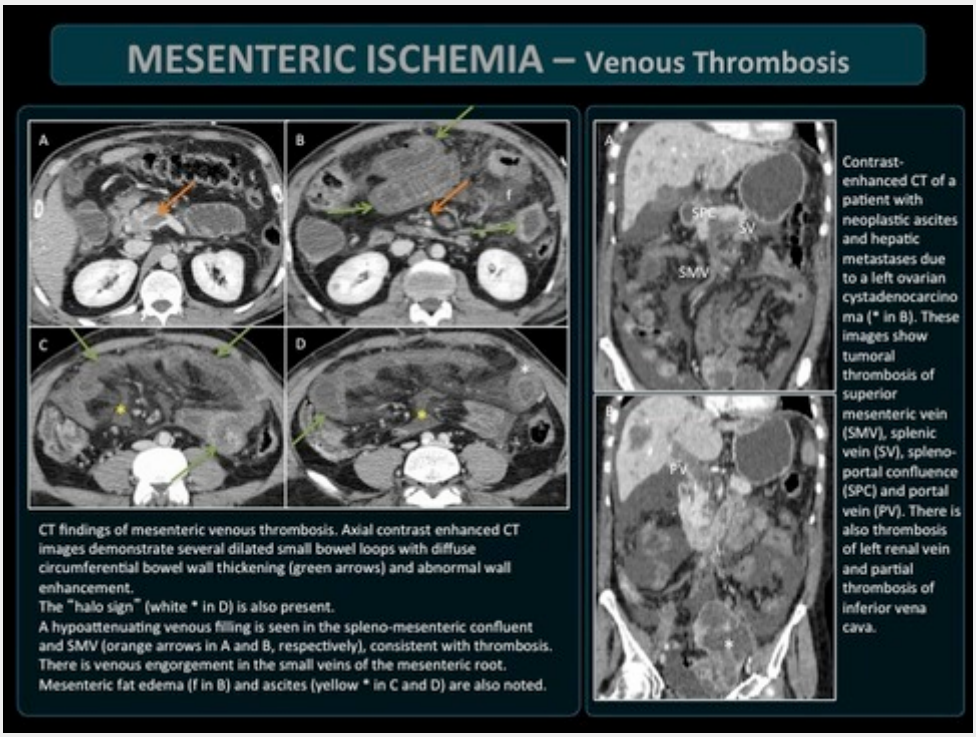

slide25.jpg

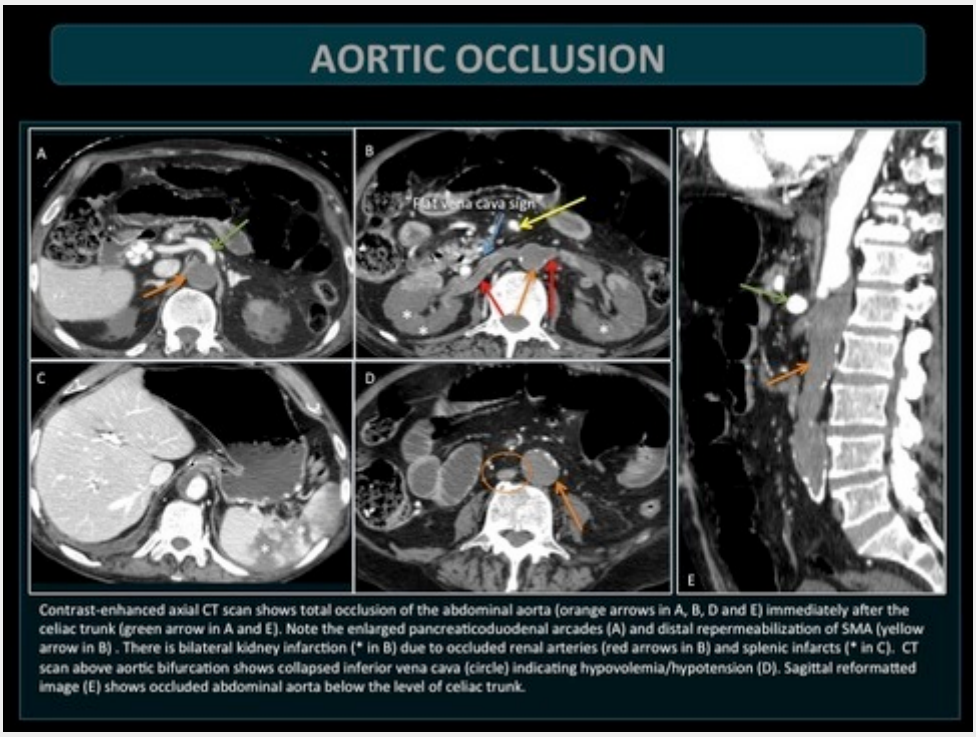

slide26.jpg

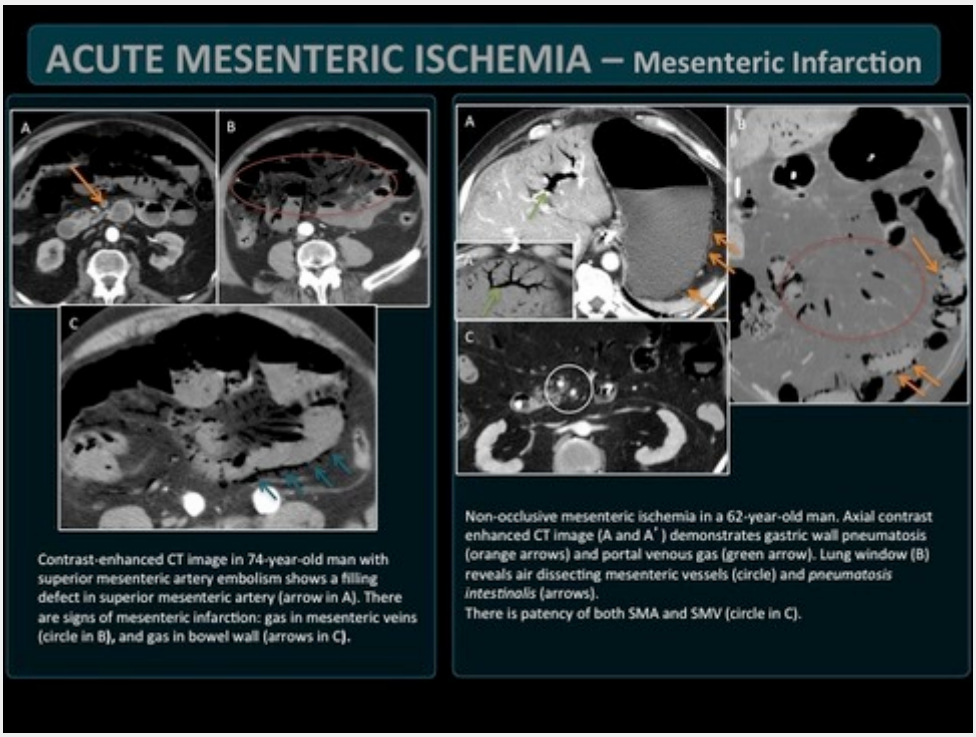

slide27.jpg

TRAUMA

- 5% of patients who suffered a blunt abdominal trauma have a mesenteric injury.
- The most common lesions are mesenteric lacerations with or without hematomas.
- The mesenteric side of the intestine is more prone to vascular tears, whereas the antimesenteric side is more prone to perforations.
- Mesenteric injury should be suspected (in the appropriated clinical setting) in a patient with reticulated increased attenuation of the mesenteric fat or a hematoma in the root of the SBM on CT.
- Other CT findings are mesenteric extravasation and hemoperitoneum, irregularity in mesenteric vessels or abrupt stop of mesenteric vessels.

slide28.jpg

Mesenteric Traumatic Injury

Axial non-enhanced CT images (A and C) demonstrate the presence of extensive and circunferential spontaneously hyperdense jejunal wall thickening (*). This finding is compatible with a focal intramural jejunal hematoma. There is also a mesenteric hematoma (orange arrow) and hemoperitoneum (white arrow).
After administration of contrast material (B and D) the hematoma is hypodense.

slide29.jpg

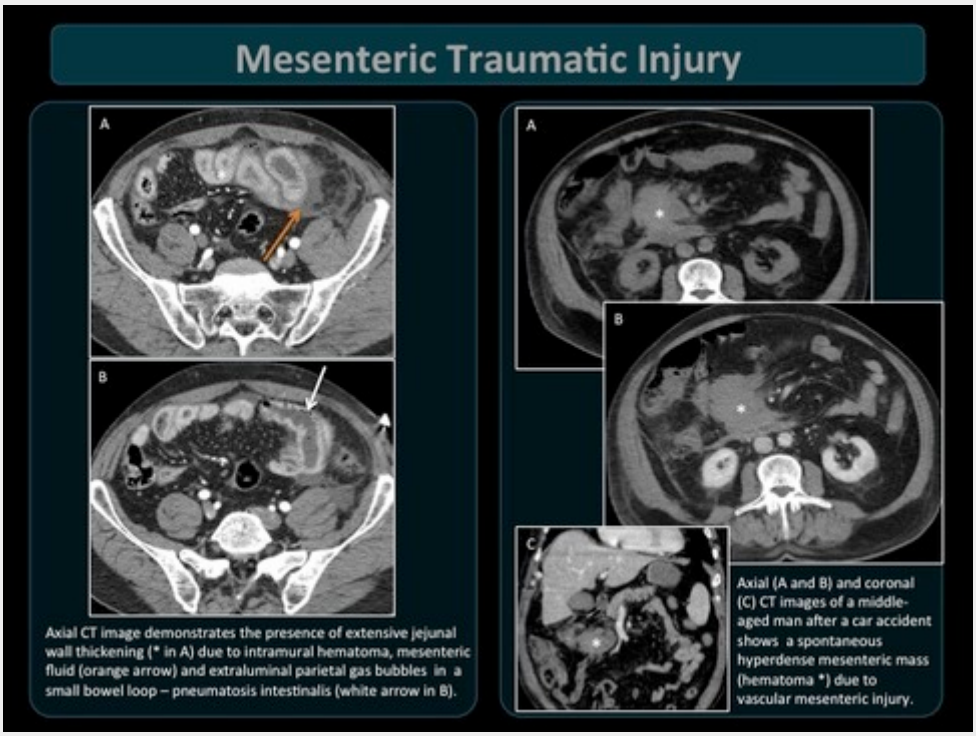

slide30.jpg

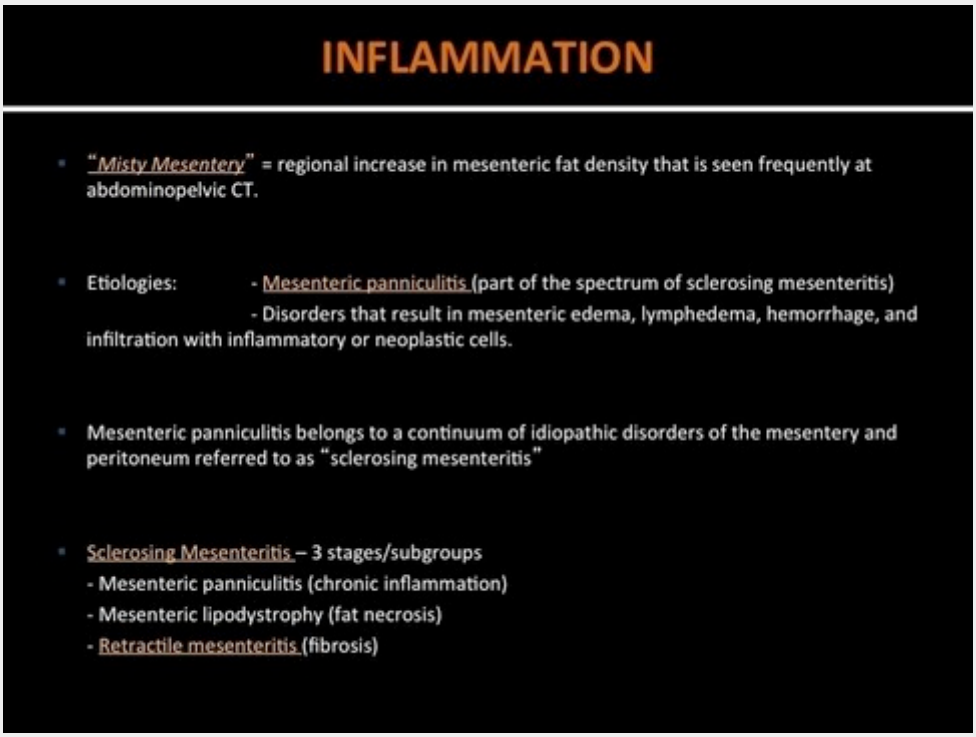

slide31.jpg

Mesenteric Panniculitis

- Chronic nonspecific inflammation involving the adipose tissue of the bowel mesentery (+ jejunal mesentery).
- May occur independently or in association with other disorders (vascullitis, granulomatous and rheumatic diseases, malignancies and pancreatitis).
- CT shows a mass-like area of heterogeneously increased fat attenuation that may displace local bowel loops but typically does not displace the surrounding mesenteric vascular structures.
- Some cases demonstrate a hyperattenuating stripe (pseudocapsule) surrounding the mass.
- Mesenteric lymph nodes are often seen within the region of segmental mesenteric stranding and may be enlarged.
- The "fat halo or ring" sign, refers to the preservation of normal fat density in the fatty tissue surrounding the mesenteric vessels and nodes.

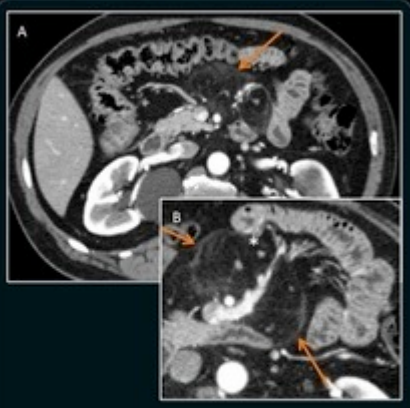

(A and B). Chronic abdominal pain in an elderly woman. Contrast-enhanced CT shows infiltration of the jejunal mesentery, set off by a pseudocapsule (arrows). A cluster of slightly enlarged nodes is present, some of them with the "fat ring sign" (* in B).

slide32.jpg

Retractile Mesenteritis

- Chronic and fulminant subgroup of sclerosing mesenteritis.
- Presence of one or more irregular fibrotic soft-tissue mesenteric masses with stellate appearance.
- The mesenteric mass sometimes shows calcifications and there may be encasement of the adjacent bowel loops and vascular structures.
- These imaging features overlap with those of carcinoid tumors, desmoid tumors and peritoneal carcinomatosis.

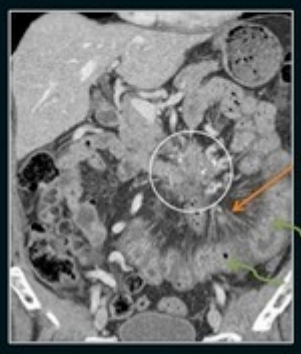

Patient with chronic abdominal pain.

Coronal reformatted contrast-enhanced CT image shows a partially calcified, fibrotic mass (circle) at the root of the jejunal mesentery. The jejunal mesenteric vessels appear engorged (arrow), and the wall of the affected portion of jejunum is thickened (curved arrows), probably due to obstruction of veins and lymphatics draining this bowel segment.

slide33.jpg

Mesenteric Adenitis

- Primary mesenteric adenitis is most frequent in children who present with right lower quadrant abdominal pain, fever and leucocytosis.
- On CT, the only finding is a cluster (more than three) of right-sided lymph nodes (usually larger than 5mm) in the small bowel mesentery or anterior to the psoas muscle, without an identifiable inflammatory condition.

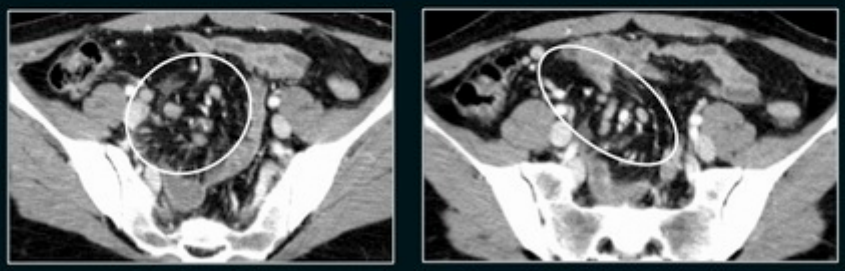

Young women with acute abdominal pain in the right lower quadrant and mild fever. Axial enhanced CT images show several enlarged mesenteric lymph nodes (circles), in the absence of other detectable abnormalities.

slide34.jpg

EDEMA

- Mesenteric edema is caused by many conditions: heart failure, hypoalbuminemia, liver cirrhosis, artery or venous thrombosis (portal and superior mesenteric vein, SMA) and vasculitic processes.
- In the systemic cause for mesenteric edema, the fluid infiltrates the SBM, causing attenuation of the mesenteric fat to increase diffusely. So, there is mesenteric haziness from the serosal surface of the intestine to the root of SBM with loss of the sharp interfaces between mesenteric vessels and fat.
- Ascitic fluid and subcutaneous tissue edema could be associated.

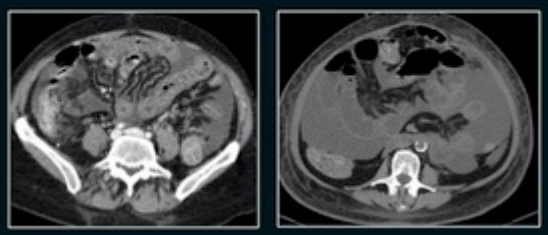

Two cases of heart failure with mesenteric haziness and ascites.

In the second patient there is also subcutaneous tissue edema.

slide35.jpg

MESENTERIC TUMORS AND TUMOR-LIKE LESIONS

- Mesenteric masses arise either from a proliferation of the intrinsic cell lines (primary tumors) or from metastatic invasion or from cellular proliferation in response to an infectious or inflammatory process.
- Primary tumors arising in the mesentery are rare. Their discovery is most often fortuitous or occurs during evaluation of vague non-specific abdominal symptoms.
- The wide diversity of different types of mesenteric masses is due to the multitude of cellular lines that compose the mesenteric structures: peritoneal surfaces, connective tissue, fatty tissue, lymphatic vessels, lymph nodes and blood vessels.
- Secondary tumors are relatively frequent as the mesentery is a frequent route of spread for malignant neoplasms through the peritoneal cavity and between the peritoneal spaces and the retroperitoneum.

slide36.jpg

Desmoid Tumor (Fibromatosis)

- Benign proliferation of fibrous tissue
- Rare: only 8% of desmoid tumors are localized to the mesentery
- Non-encapsulated
- Occurs sporadically, but common in patients with Gardner Syndrome (who have undergone abdominal surgery).
- Soft-tissue mass with well-demarcated or poorly defined borders and strands radiating into the adjacent mesenteric fat.
- Can infiltrate adjacent organs or grow into the abdominal wall musculature – locally aggressive.
- Isoattenuating relative to muscle with areas of low attenuation caused by necrosis (in larger lesions).

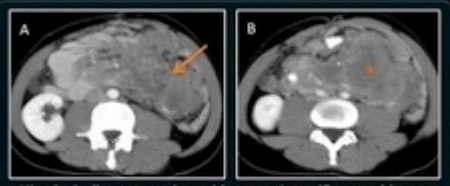

Histologically proven desmoid tumor in a 45 year-old man with insidious abdominal pain and history of familial adenomatous polyposis syndrome. (A and B) Axial contrast-enhanced CT images of the lower abdomen show a soft-tissue mass in the mesentery (arrow in A). The attenuation of the mass is similar to that of the psoas muscles. There are central areas of lower attenuation (* in B).

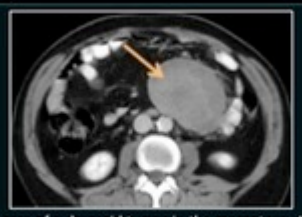

Another case of a desmoid tumor in the mesentery. Young man without history of familial adenomatous polyposis syndrome. There is a well defined soft tissue mass in the mesentery (arrow).

slide37.jpg

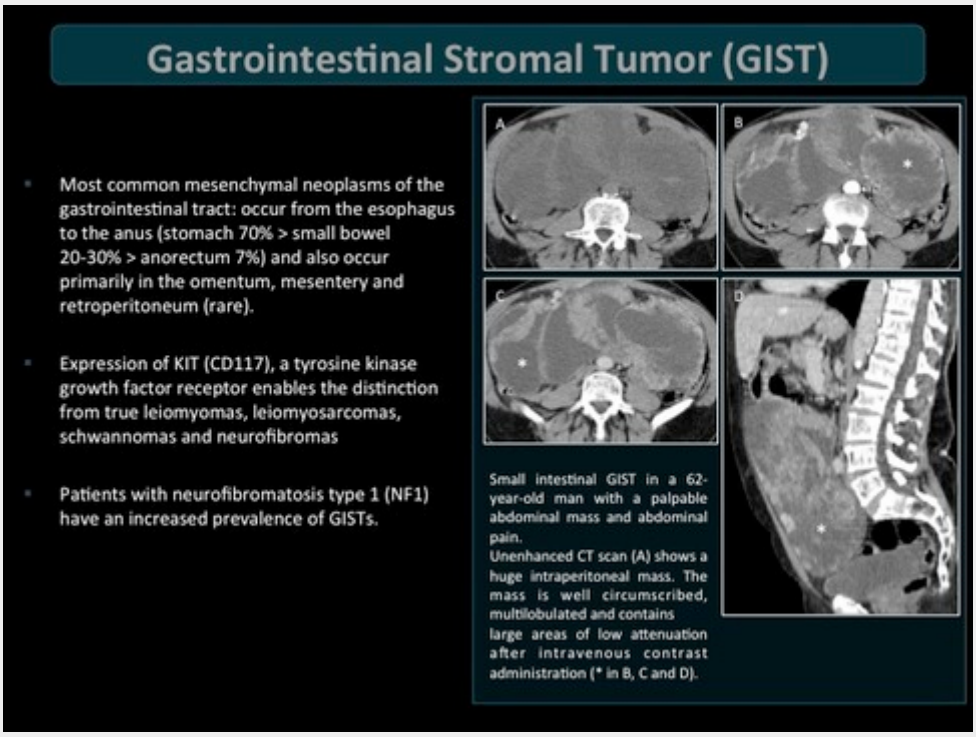

slide38.jpg

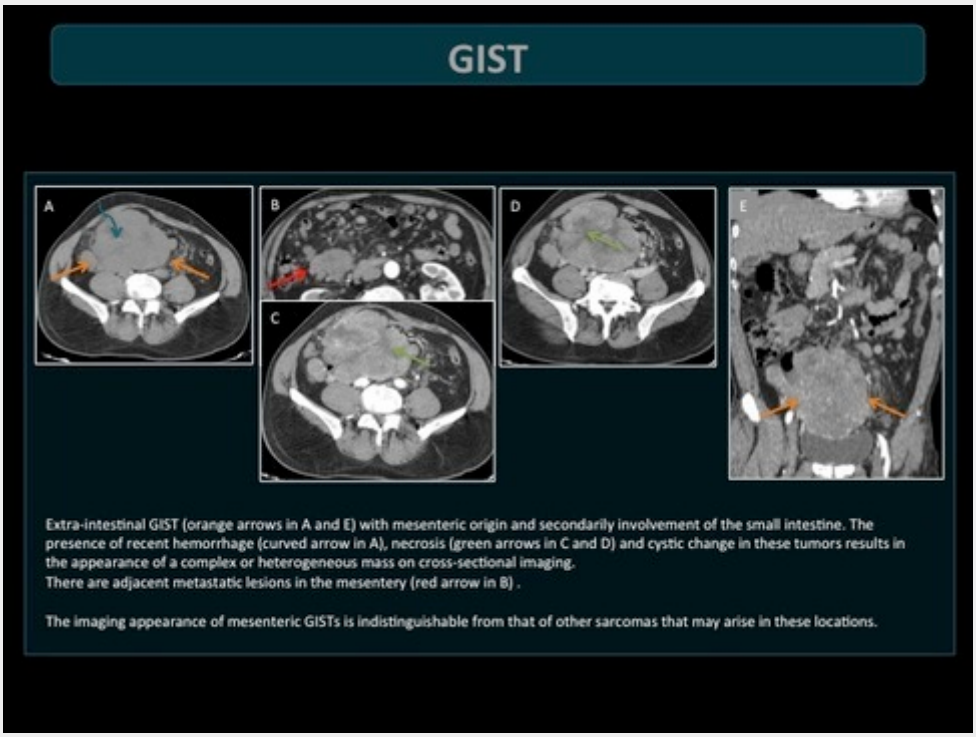

slide39.jpg

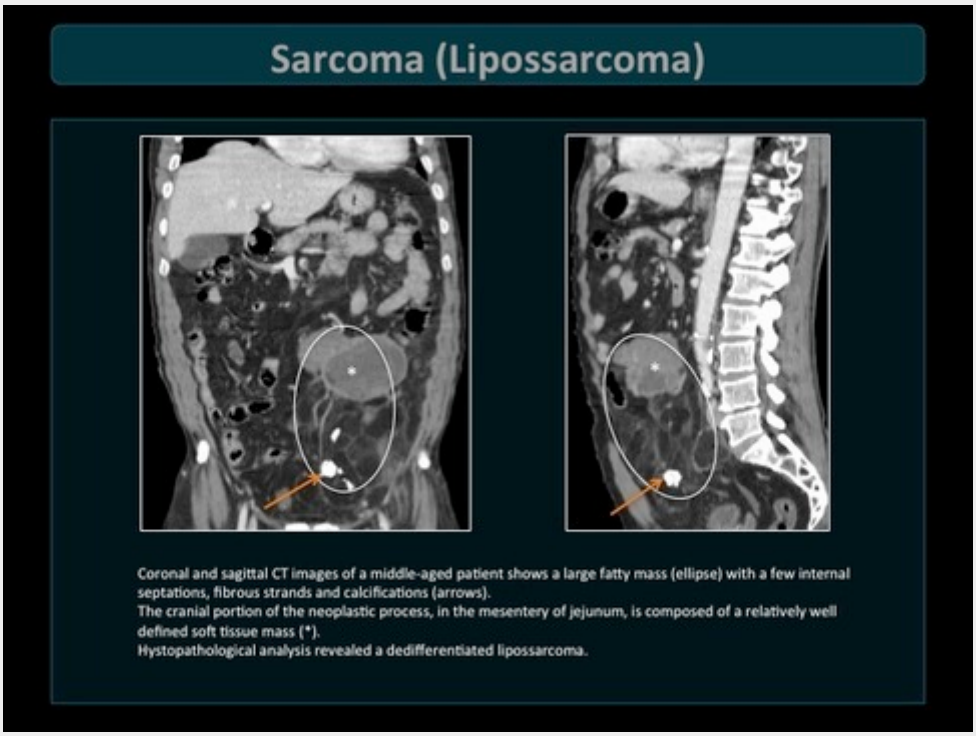

slide40.jpg

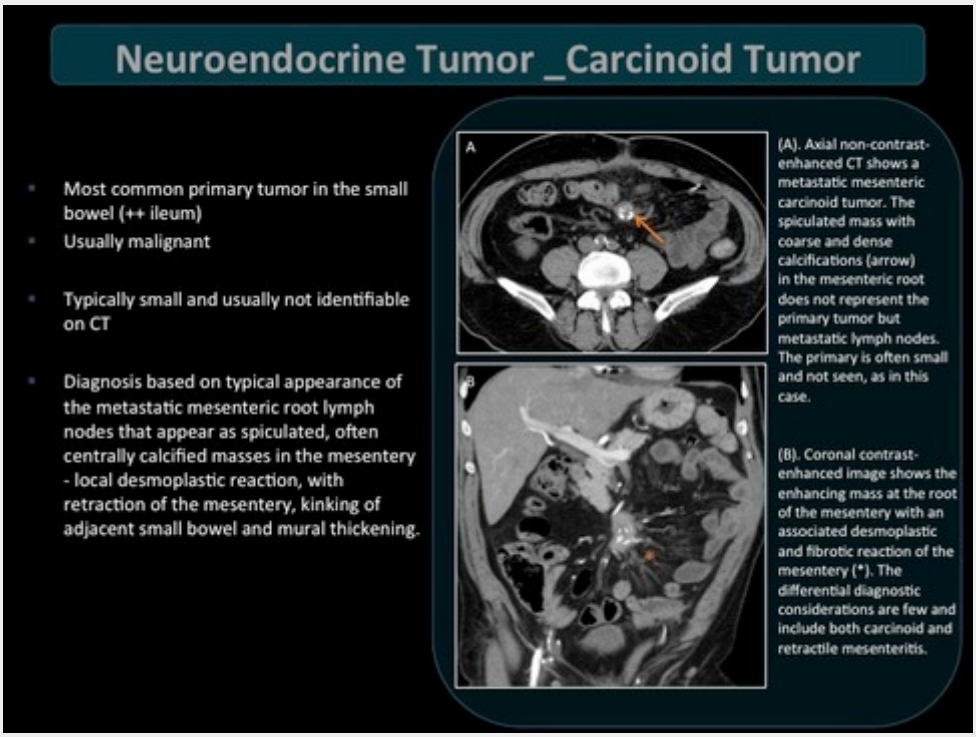

slide41.jpg

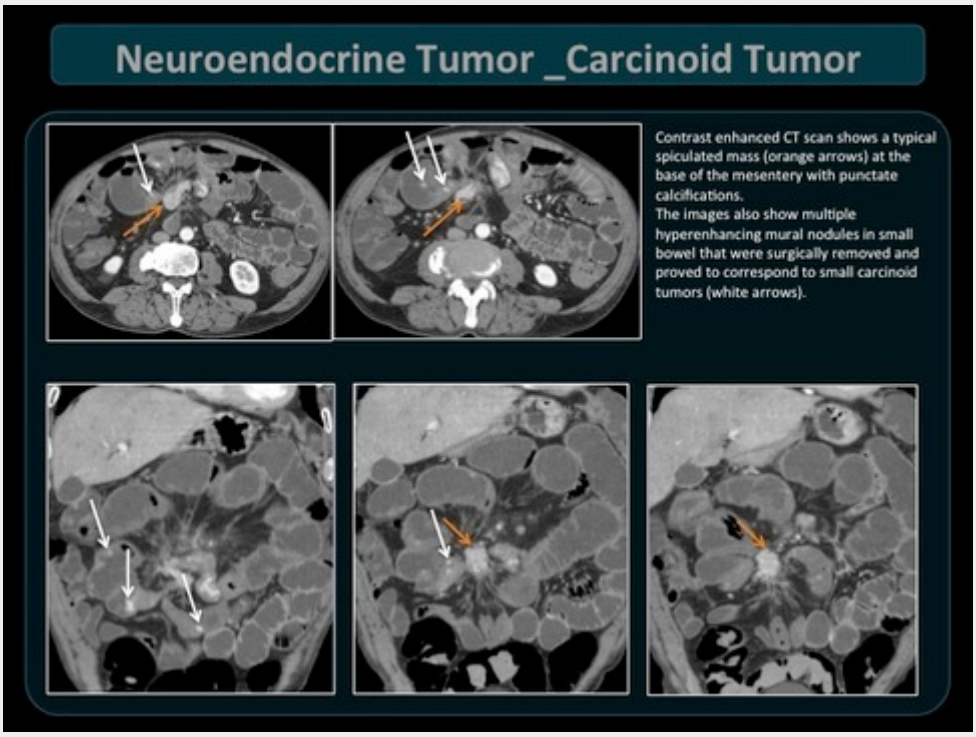

slide42.jpg

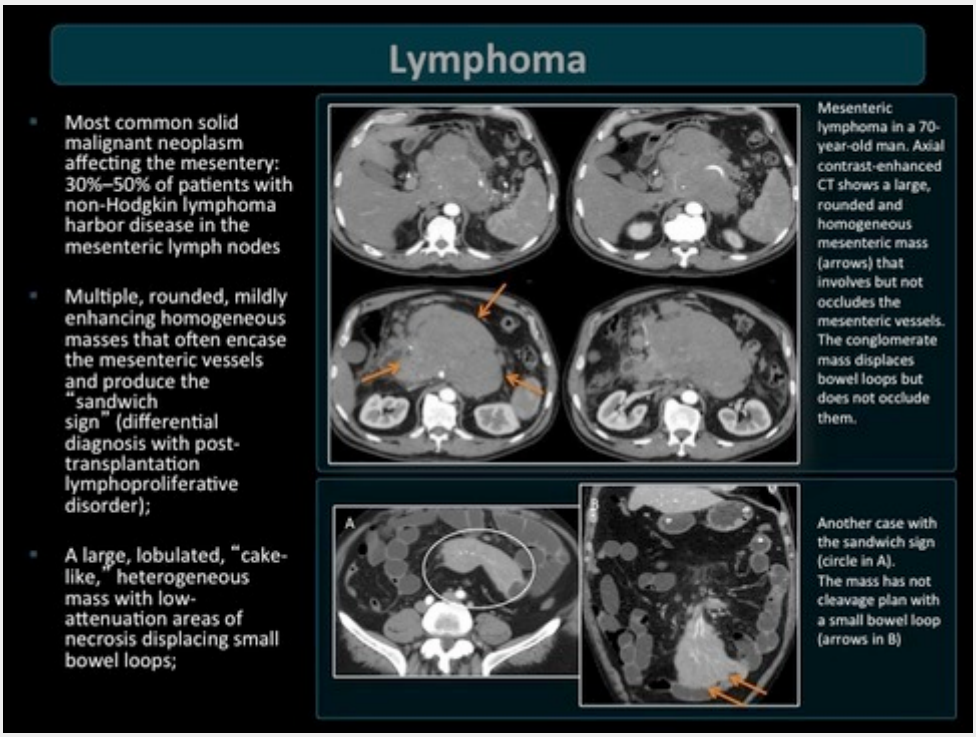

slide43.jpg

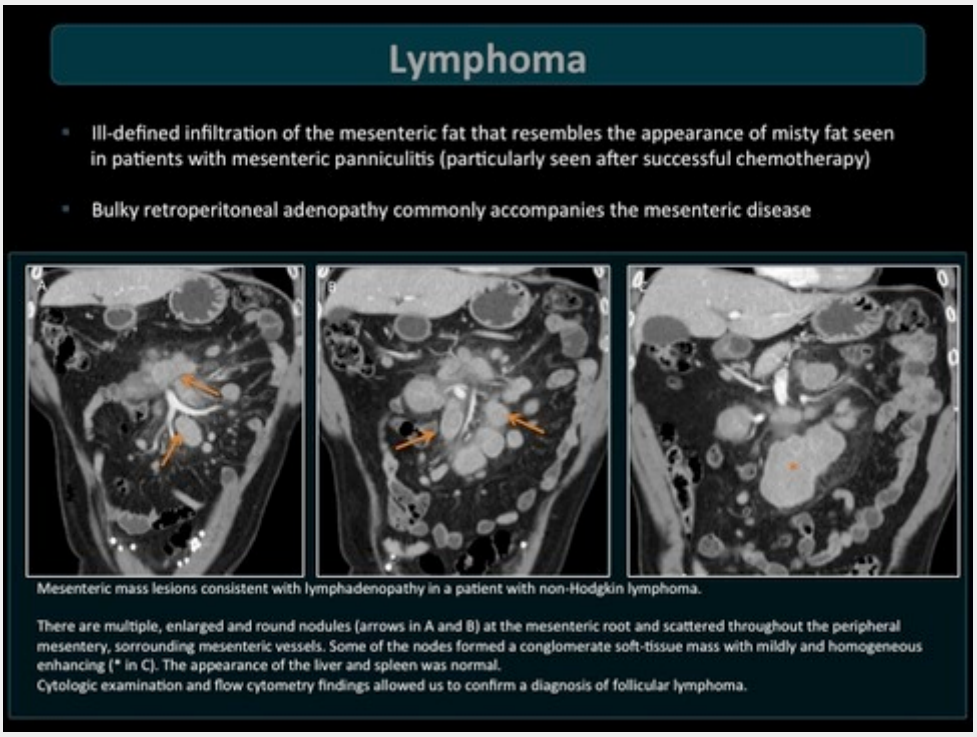

slide44.jpg

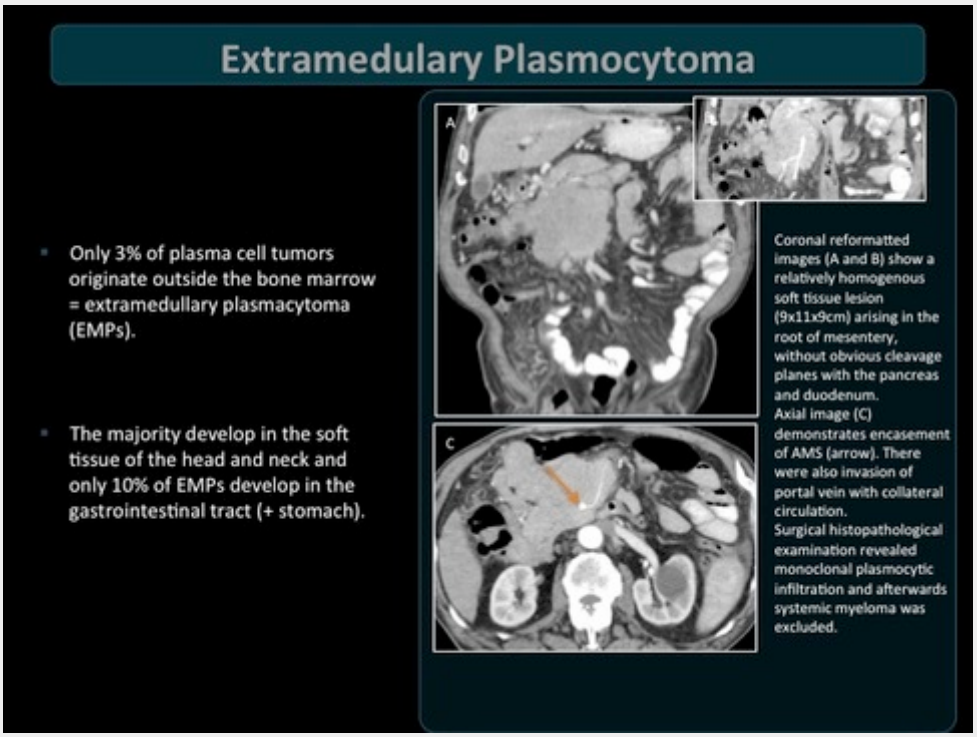

slide45.jpg

Castleman Disease

- Castleman disease or angiofollicular lymph node hyperplasia, is a rare, generally benign disease characterized by atypical proliferation of lymphocytes.
- Most often found in the mediastinum (67%) > neck (10-15%); abdomen and pelvis (10-15%).

- Most commonly manifests as a localized mass or masses (lymphadenopathy).
- Smaller tumors (<5 cm) display homogeneous contrast enhancement; larger tumors (>5 cm) show heterogeneous enhancement correlated with central necrosis and degeneration.
- Striking contrast enhancement of enlarged nodal masses at CT represents the only suggestive feature of this entity.

- Can display a variety of calcification patterns: punctate, coarse and peripheral.

- Increased risk of lymphoma

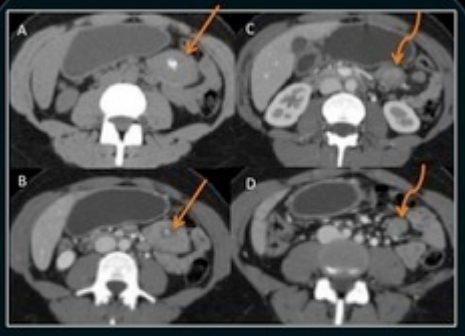

Axial unenhanced CT image demonstrating a well-defined mesenteric mass with punctate calcifications (arrow in A).

After intravenous contrast administration there was slight heterogenous enhancement (low attenuation central area) (arrow in B).
There were two other small rounded nodules, adjacent to the previous mass described (curved arrows in C and D).

slide46.jpg

Mesenteric Cyst

- Generic descriptive term for cystic mass arising in mesentery or omentum.
- May refer to cystic lymphangioma unless otherwise specified.

- CT appearance is that of a circumscribed cystic mass in mesentery or retroperitoneum with variable density and non-enhancing content.
- Water-density (near 0 HU), chylous (< -20 HU), rarely hemorrhagic.
- ± fine calcifications along cyst wall, with or without septa.

- Should be differentiated from loculated ascites, gastrointestinal duplication cysts, pancreatic pseudocyst, cystic pancreatic tumor and peritoneal inclusion cyst.

Patient with neurofibromatosis and multiple subcutaneous neurofibromas (orange arrows).
CT shows a near-water-density mass in the mesentery (white arrow in A) without contrast enhancement (B and C), that correspond to a lymphoepithelial cyst.

slide47.jpg

Acessory spleen

- One or more small splenic masses may develop in one of the peritoneal folds early in fetal life.
- An accessory spleen is present in about 10% of individuals, commonly situated near the hilum of the spleen or adjacent to the tail of the pancreas.

A 3,5cm well-defined round mass (orange arrows) was incidentally discovered in a 35 year-old man. Its attenuation is identical to that of splenic tissue, both before (A) and after administration of contrast medium (B – arterial phase; C – portal phase; D – late phase).

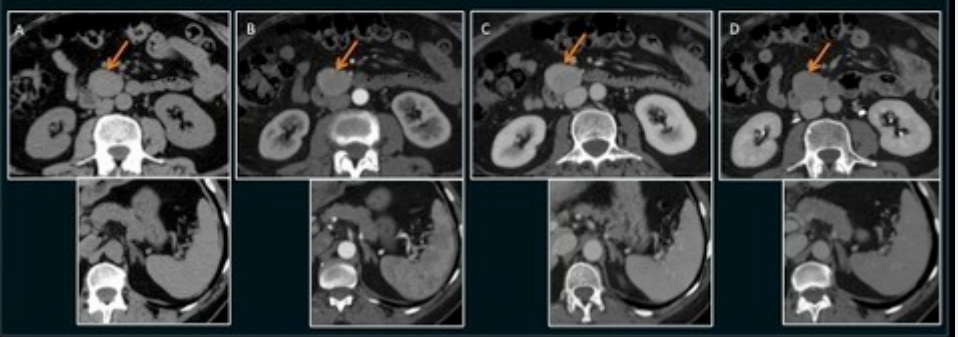

slide48.jpg

Malignant Peritoneal Mesothelioma

- Rare neoplasm with a rapidly fatal course. Half of the cases are related to asbestos exposure
- Solid, enhancing soft-tissue mass within the mesentery, omentum, or peritoneum; infiltrating mass; or multiple small nodules.
- 3 types: - "dry-painful" type: multiple small peritoneal masses or a single dominant mass. Little or no ascites is identified.
- - "wet" type: ascites associated with widespread small nodules and plaques, without a dominant solid mass.
  - combination of these clinical subtypes, in which patients may present with pain and ascites
- It has a tendency to spread along serosal surfaces and for direct invasion of both solid and hollow intra-abdominal organs (+ colon and liver).

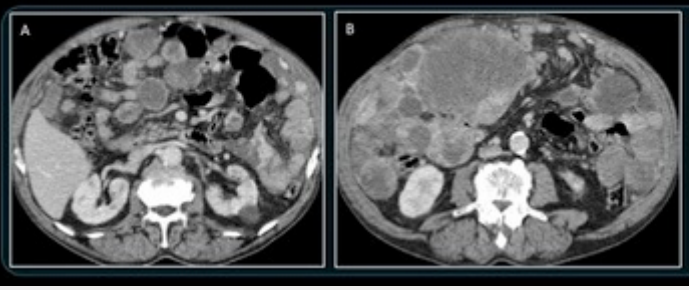

Axial contrast-enhanced CT scan shows "dry-painful" type of malignant peritoneal mesothelioma in a 73-year-old man.
There is a dominant mass in the right abdominal quadrants and other multiple small peritoneal, omental and mesenteric metastases. Small ascites was identified in the pelvis.

slide49.jpg

Secondary Involvement : Infectious and Inflammatory, Neoplastic and Tumor-Like lesions

- The pathologic conditions that may secondarily affect the peritoneum and peritoneal cavity, the mesenteries and omentum, can be categorized into three broad groups: metastatic neoplasms, infectious and inflammatory lesions, and miscellaneous tumors and tumorlike lesions.
- The root of the mesentery is a connecting way between several intraperitoneal compartments and the retroperitoneum, namely lesser sac, supramesocolic compartment, both inframesocolic compartments and inferior retroperitoneum.
- There are different ways of involvement:
  - Direct extension
  - Extension along ligaments and peritoneal folds
  - Neural plexus extension
  - Lymphatic vessel extension.
- Closely related to retroperitoneal pathology because there is not a clear limit between the retroperitoneum and the mesentery.

slide50.jpg

Mesenteric Metastases

- Metastases from carcinomas of the colon ovarian, breast, lung and melanoma can spread to mesenteric lymph nodes.
- The most common malignant process in the peritoneal cavity.
- However, the degree of nodal enlargement seen in mesenteric metastatic disease is less pronounced than that seen in mesenteric lymphoma.
- The distribution of involved nodes is comparatively more localized in metastatic disease.

Metastatic melanoma in a 55-year-old man. Axial post-contrast CT image demonstrates several enhancing masses in the small bowel mesentery (arrows) that represented mesenteric implants of melanoma.
The small intestine and its mesentery are the most common site of gastrointestinal metastases from melanoma.

slide51.jpg

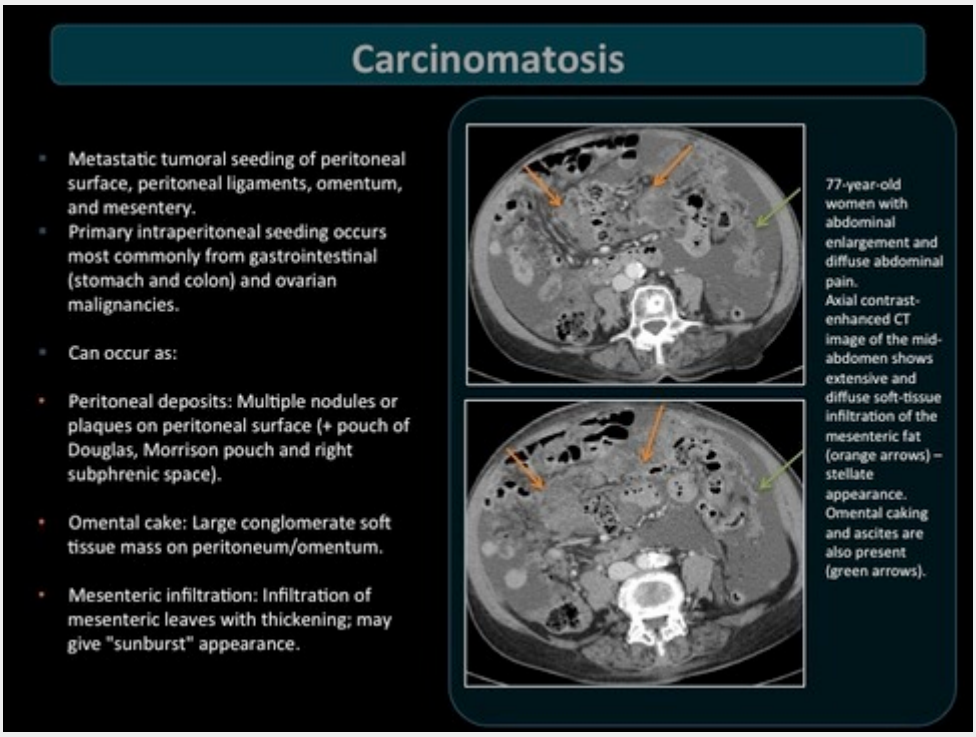

slide52.jpg

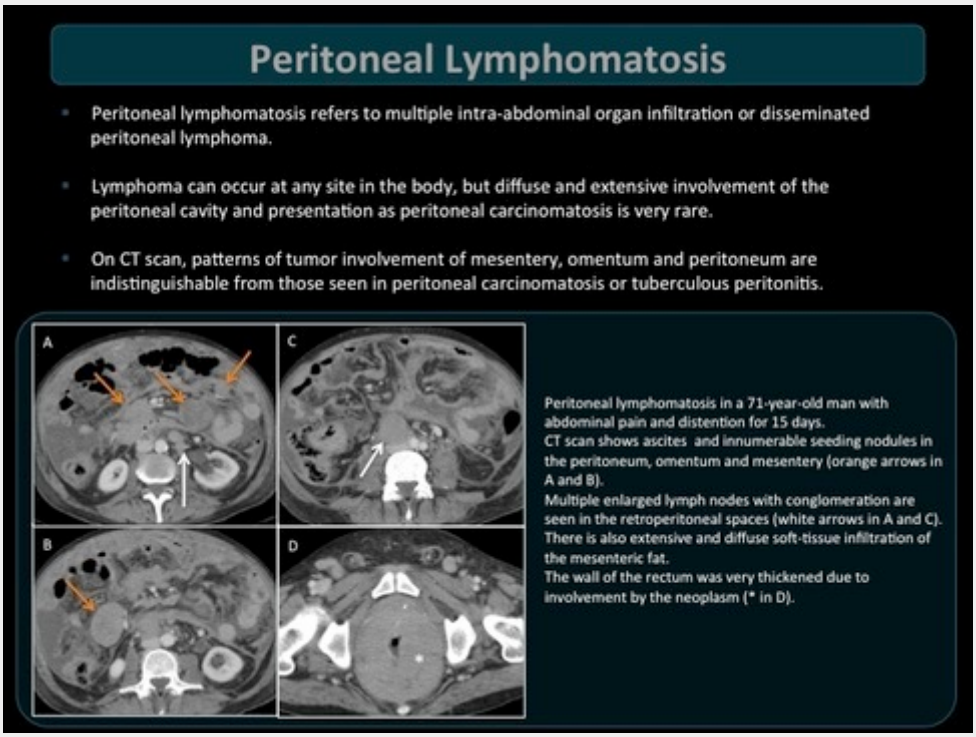

slide53.jpg

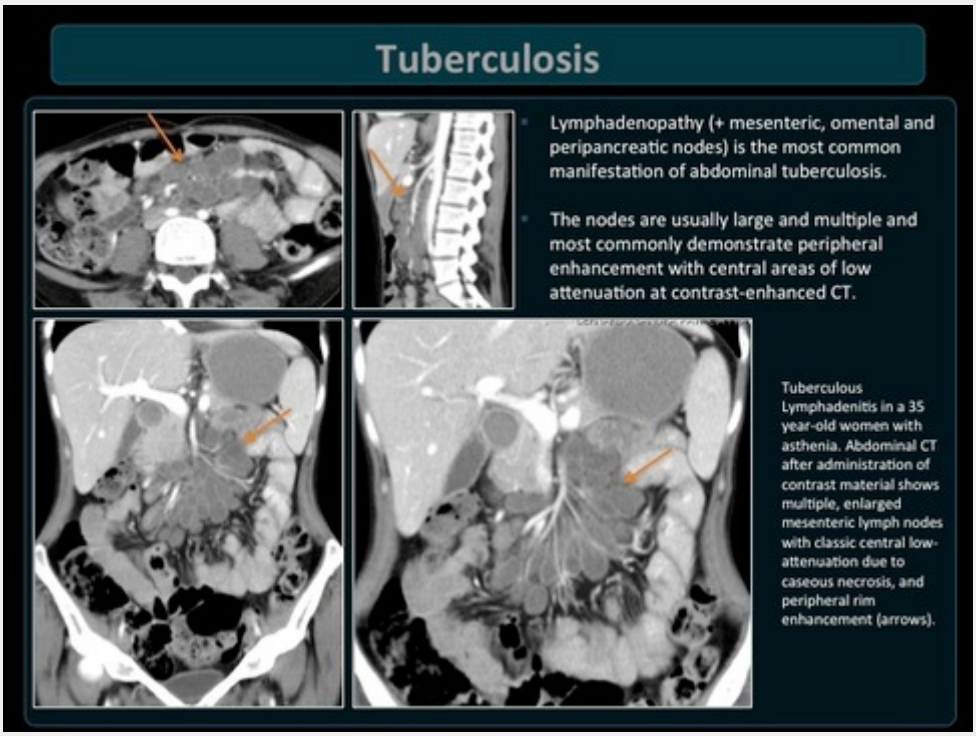

slide54.jpg

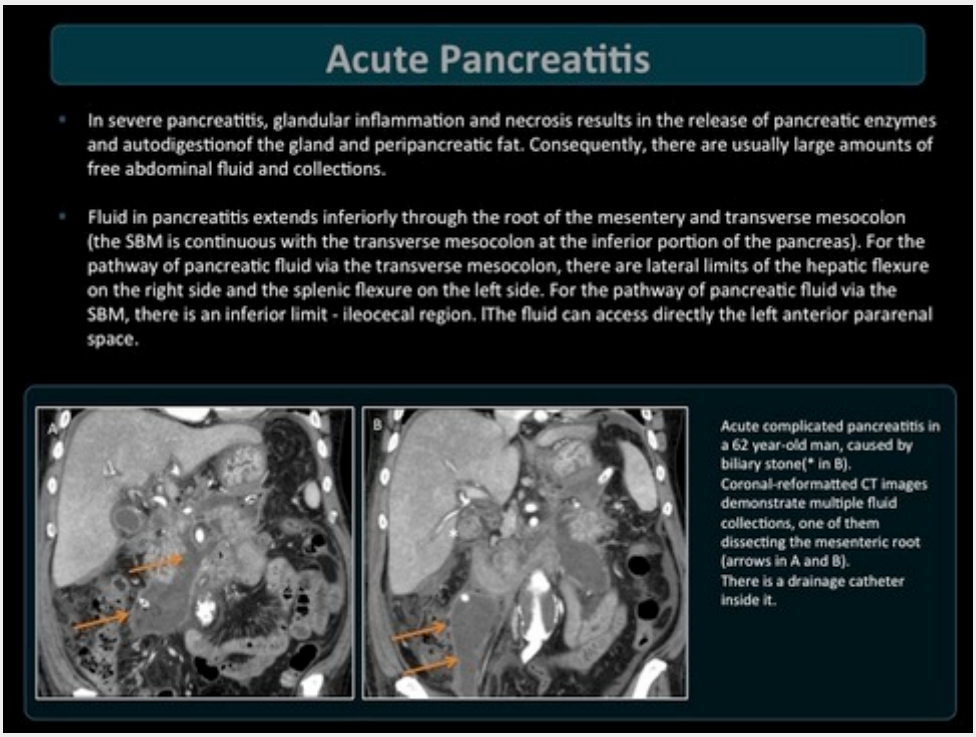

slide55.jpg

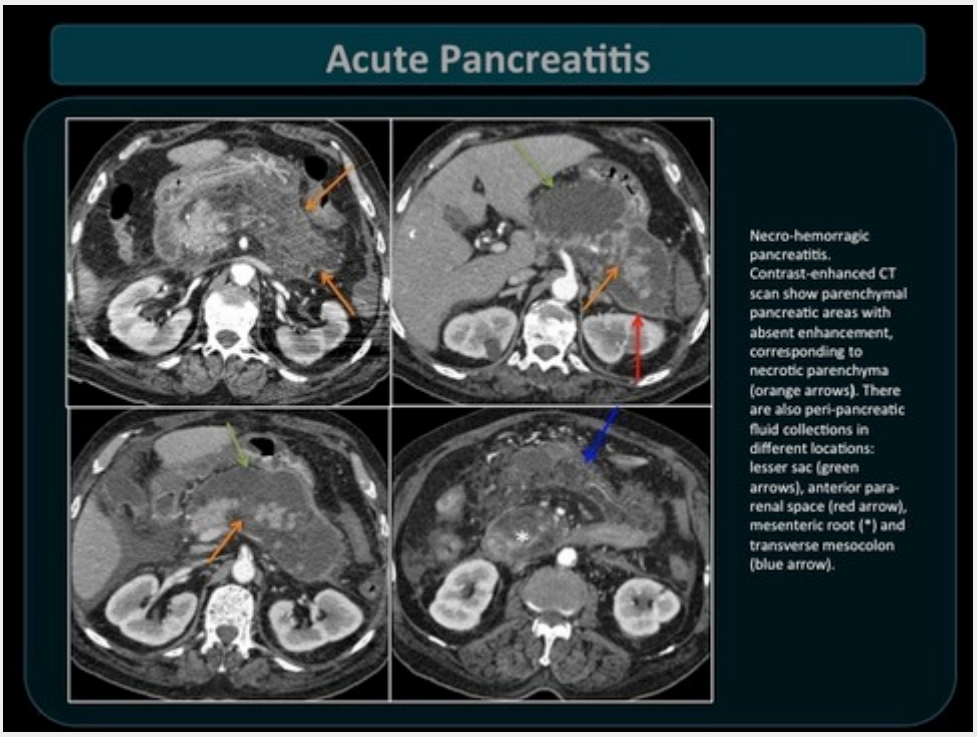

slide56.jpg

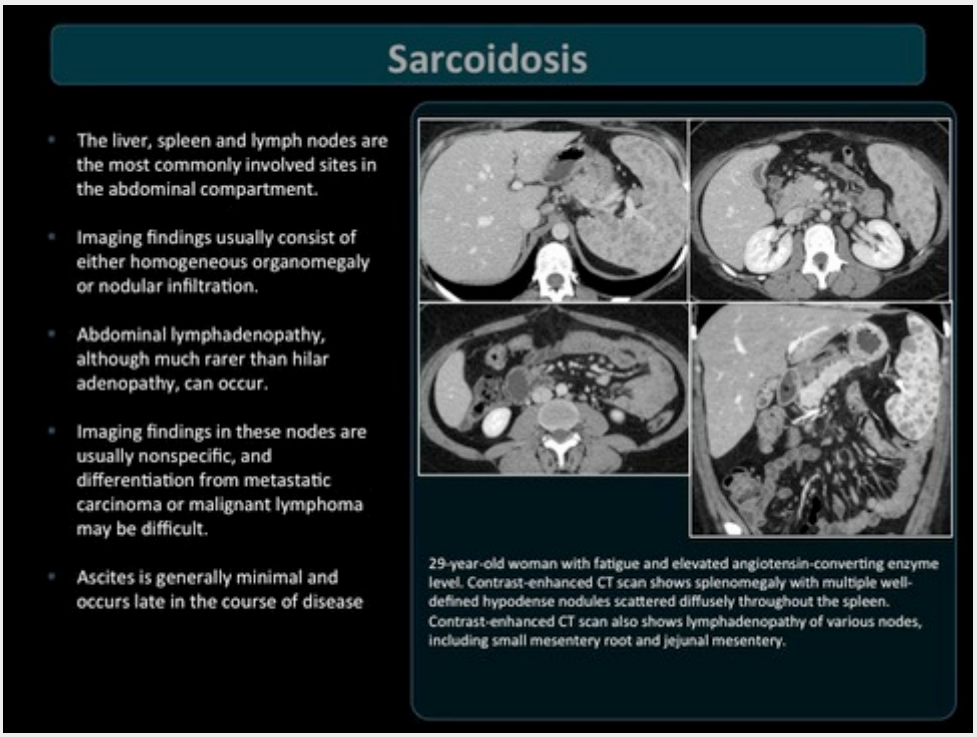

slide57.jpg

CONCLUSIONS

- A thorough understanding of peritoneal anatomy, specifically the SBM and its communications with other intraperitoneal spaces and retroperitoneum, results in a more accurate radiological interpretation of CT images.
- For radiologists, is important to understand not only the anatomy of the root of the mesentery and the small bowel mesentery itself, but also to know the many pathological conditions by which it could be affected.

slide58.jpg

REFERENCES

Root of the Small-Bowel Mesentery: Correlative Anatomy and CT Features of Pathologic Conditions. Okino Y, Kiyosue H, Mori H, Komatsu E, Matsumoto S, Yamada Y, Suzuki K, Tomonari K. Radiographics. 2001 Nov-Dec;21(6): 1475-90.

Secondary tumors and tumorlike lesions of the peritoneal cavity: imaging features with pathologic correlation. Levy AD, Shaw JC, Sobin LH. Radiographics. 2009 Mar-Apr;29(2):347-73.

Unusual nonneoplastic peritoneal and subperitoneal conditions: CT findings. Pickhardt PJ, Bhalla S. Radiographics. 2005 May-Jun;25(3):719-30.

Peritoneal and retroperitoneal anatomy and its relevance for cross-sectional imaging. Tirkes T, Sandrasegaran K, Patel AA, Hollar MA, Tejada JG, Tann M, Akisik FM, Lappas JC. Radiographics. 2012 Mar-Apr;32(2):437-51. doi: 10.1148/rg.322115032.

Mesenteric neoplasms: CT appearances of primary and secondary tumors and differential diagnosis. Sheth S, Horton KM, Garland MR, Fishman EK. Radiographics. 2003 Mar-Apr;23(2):457-73; quiz 535-6.

From the archives of the AFIP: benign fibrous tumors and tumorlike lesions of the mesentery: radiologic-pathologic correlation. Levy AD, Rimola J, Mehrotra AK, Sobin LH. Radiographics. 2006 Jan-Feb;26(1):245-64.

CT diagnosis of acute mesenteric ischemia from various causes. Furukawa A, Kanasaki S, Kono N, Wakamiya M, Tanaka T, Takahashi M, Murata K. AJR Am J Roentgenol. 2009 Feb;192(2):408-16.

CT of internal hernias. Takeyama N, Gokan T, Ohgiya Y, Satoh S, Hashizume T, Hataya K, Kushiro H, Nakanishi M, Kusano M, Munechika H. Radiographics. 2005 Jul-Aug;25(4):997-1015.

slide59.jpg

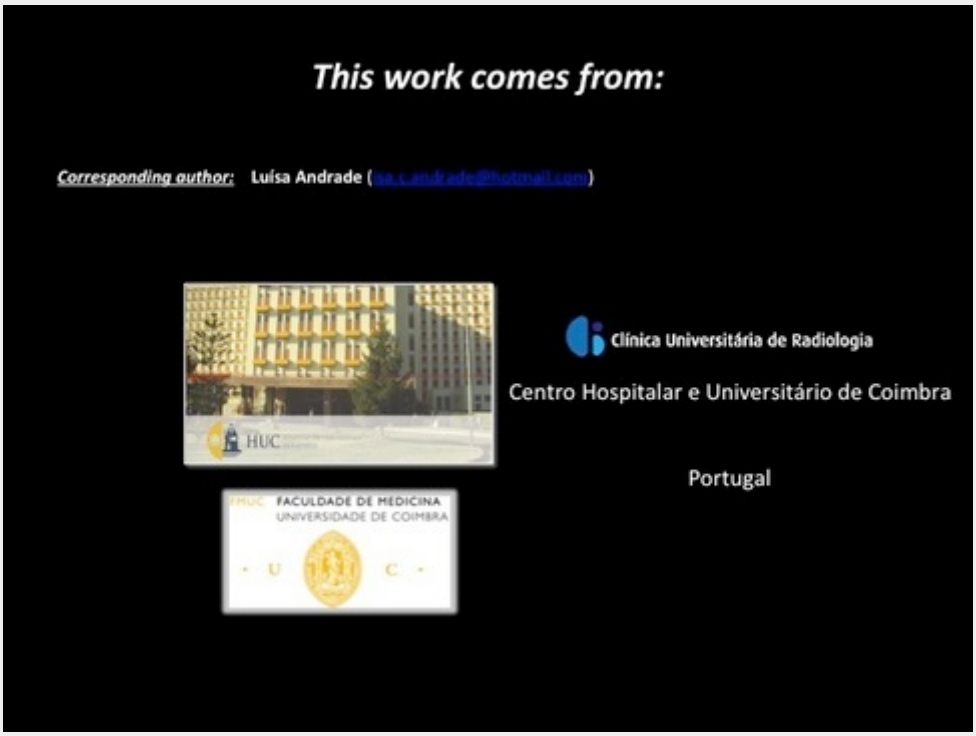
This work comes from:
Corresponding author: Luísa Andrade (sa.c.andrade@hotmail.com)
HUC
Clínica Universitária de Radiologia
Centro Hospitalar e Universitário de Coimbra
Portugal
FACULDADE DE MEDICINA
UNIVERSIDADE DE COIMBRA
U
C